III. Syndesmology

Introduction

THE BONES of the skeleton are joined to one another at different parts of their surfaces, and such connections are termed **Joints** or **Articulations.** Where the joints are *immovable,* as in the articulations between practically all the bones of the skull, the adjacent margins of the bones are almost in contact, being separated merely by a thin layer of fibrous membrane, named the **sutural ligament.** In certain regions at the base of the skull this fibrous membrane is replaced by a layer of cartilage. Where *slight movement* combined with great strength is required, the osseous surfaces are united by tough and elastic **fibrocartilages,** as in the joints between the vertebral bodies, and in the interpubic articulation. In the *freely movable* joints the surfaces are completely separated; the bones forming the articulation are expanded for greater convenience of mutual connection, covered by **cartilage** and enveloped by **capsules** of fibrous tissue. The cells lining the interior of the fibrous capsule form an imperfect membrane—the **synovial membrane**—which secretes a lubricating fluid. The joints are strengthened by strong fibrous bands called **ligaments,** which extend between the bones forming the joint. *1*

Bone.—Bone constitutes the fundamental element of all the joints. In the long bones, the extremities are the parts which form the articulations; they are generally somewhat enlarged; and consist of spongy cancellous tissue with a thin coating of compact substance. In the flat bones, the articulations usually take place at the edges; and in the short bones at various parts of their surfaces. The layer of compact bone which forms the joint surface, and to which the articular cartilage is attached, is called the **articular lamella.** It differs from ordinary bone tissue in that it contains no Haversian canals, and its lacunæ are larger and have no canaliculi. The vessels of the cancellous tissue, as they approach the articular lamella, turn back in loops, and do not perforate it; this layer is consequently denser and firmer than ordinary bone, and is evidently designed to form an unyielding support for the articular cartilage. *2*

Cartilage.—Cartilage is a non-vascular structure which is found in various parts of the body—in adult life chiefly in the joints, in the parietes of the thorax, and in various tubes, such as the trachea and bronchi, nose, and ears, which require to be kept permanently open. In the fetus, at an early period, the greater part of the skeleton is cartilaginous; as this cartilage is afterward replaced by bone, it is called **temporary,** in contradistinction to that which remains unossified during the whole of life, and is called **permanent.** *3*

Cartilage is divided, according to its minute structure, into **hyaline cartilage, white fibrocartilage,** and **yellow** or **elastic fibrocartilage.** *4*

Hyaline Cartilage.—Hyaline cartilage consists of a gristly mass of a firm consistence, but of considerable elasticity and pearly bluish color. Except where it coats the articular ends of bones, it is covered externally by a fibrous membrane, the **perichondrium,** from the vessels of which it imbibes its nutritive fluids, being itself destitute of bloodvessels. It contains no nerves. Its intimate structure is very simple. If a thin slice be examined under the microscope, it will be found to consist of cells of a rounded or bluntly angular form, lying in groups of two or more in a *5*

granular or almost homogeneous matrix (Fig. 292). The cells, when arranged in groups of two or more, have generally straight outlines where they are in contact with each other, and in the rest of their circumference are rounded. They consist of clear translucent protoplasm in which fine interlacing filaments and minute granules are sometimes present; imbedded in this are one or two round nuclei, having the usual intranuclear network. The cells are contained in cavities in the matrix, called**cartilage lacunæ;** around these the matrix is arranged in concentric lines, as if it had been formed in sucessive portions around the cartilage cells. This constitutes the so-called**capsule of the space.** Each lacuna is generally occupied by a single cell, but during the division of the cells it may contain two, four, or eight cells.

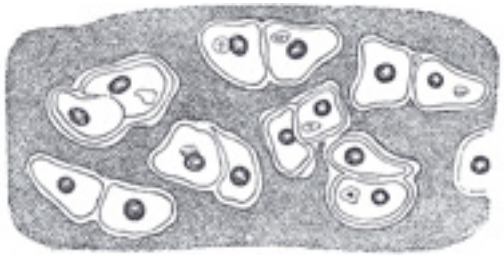

FIG. 292– Human cartilage cells from the cricoid cartilage. (See enlarged image)

The matrix is transparent and apparently without structure, or else presents a dimly granular appearance, like ground glass. Some observers have shown that the matrix of hyaline cartilage, and especially of the articular variety, after prolonged maceration, can be broken up into fine fibrils. These fibrils are probably of the same nature, chemically, as the white fibers of connective tissue. It is believed by some histologists that the matrix is permeated by a number of fine channels, which connect the lacunæ with each other, and that these canals communicate with the lymphatics of the perichondrium, and thus the structure is permeated by a current of nutrient fluid. *6*

Articular cartilage, costal cartilage, and **temporary cartilage** are all of the hyaline variety. They present differences in the size, shape, and arrangement of their cells. *7*

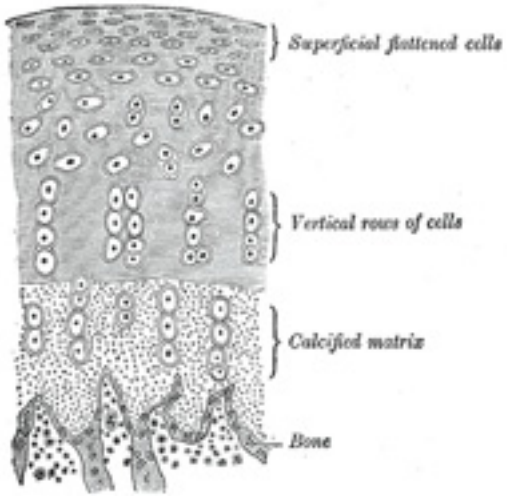

FIG. 293– Vertical section of articular cartilage. (See enlarged image)

FIG. 294– Costal cartilage from a man, aged seventy-six years, showing the development of fibrous structure in the matrix. In several portions of the specimen two or three generations of cells are seen enclosed in a parent cell wall. Highly magnified. (See enlarged image)

In **Articular Cartilage** (Fig. 293), which shows no tendency to ossification, the matrix is finely granular; the cells and nuclei are small, and are disposed parallel to the surface in the superficial part, while nearer to the bone they are arranged in vertical rows. Articular cartilages have a tendency to split in a vertical direction; in disease this tendency becomes very manifest. The free surface of articular cartilage, where it is exposed to friction, is not covered by perichondrium, although a layer of connective tissue continuous with that of the synovial membrane can be traced in the adult over a small part of its circumference, and here the cartilage cells are more or less branched and pass insensibly into the branched connective tissue corpuscles of the synovial membrane. Articular cartilage forms a thin incrustation upon the joint surfaces of the bones, and its elasticity enables it to break the force of concussions, while its smoothness affords ease and freedom of movement. It varies in thickness according to the shape of the articular surface on which it lies; where this is convex the cartilage is thickest at the center, the reverse being the case on concave articular surfaces. It appears to derive its nutriment partly from the vessels of the neighboring synovial membrane and partly from those of the bone upon which it is implanted. Toynbee has shown that the minute vessels of the cancellous tissue as they approach the articular lamella dilate and form arches, and then return into the substance of the bone. *8*

In **Costal Cartilage** the cells and nuclei are large, and the matrix has a tendency to fibrous striation, especially in old age (Fig. 294). In the thickest parts of the costal cartilages a few large vascular channels may be detected. This appears, at first sight, to be an exception to the statement that cartilage is a non-vascular tissue, but is not so really, for the vessels give no branches to the cartilage substance itself, and the channels may rather be looked upon as involutions of the perichondrium. The xiphoid process and the cartilages of the nose, larynx, and trachea (except the epiglottis and corniculate cartilages of the larynx, which are composed of elastic fibrocartilage) resemble the costal cartilages in microscopic characteristics. The arytenoid cartilage of the larynx shows a transition from hyaline cartilage at its base to elastic cartilage at the apex. *9*

The hyaline cartilages, especially in adult and advanced life, are prone to calcify—that is to say, to have their matrix permeated by calcium salts without any appearance of true bone. The process of calcification occurs frequently, in such cartilages as those of the trachea and in the costal cartilages, where it may be succeeded by conversion into true bone. *10*

White Fibrocartilage.—White fibrocartilage consists of a mixture of white fibrous tissue and cartilaginous tissue in various proportions; to the former of these constituents it owes its flexibility and toughness, and to the latter its elasticity. When examined under the microscope it is found to be made up of fibrous connective tissue arranged in bundles, with cartilage cells between the bundles; the cells to a certain extent resemble tendon cells, but may be distinguished from them by being surrounded by a concentrically striated area of cartilage matrix and by being less flattened (Fig. 295). The white fibrocartilages admit of arrangement into four groups—**interarticular, connecting, circumferential,** and**stratiform.** *11*

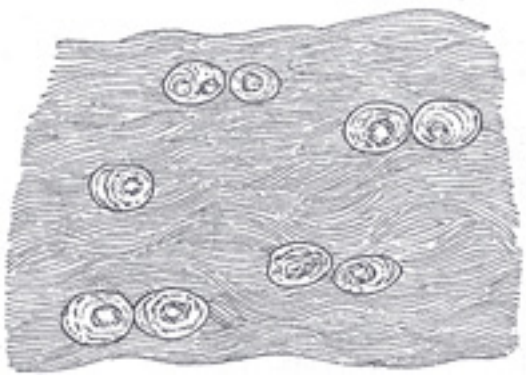

FIG. 295– White fibrocartilage from an intervertebral fibrocartilage. (See enlarged image)

1. The **Interarticular Fibrocartilages** (*menisci*) are flattened fibrocartilaginous plates, of a round, oval, triangular, or sickle-like form, interposed between the articular cartilages of certain joints. They are free on both surfaces, usually thinner toward the center than at the circumference, and held in position by the attachment of their margins and extremities to the surrounding ligaments. The synovial membranes of the joints are prolonged over them. They are found in the temporomandibular, sternoclavicular, acromioclavicular, wrist, and knee joints—*i. e.,* in those joints which are most exposed to violent concussion and subject to frequent movement. Their uses are to obliterate the intervals between opposed surfaces in their various motions; to increase the depths of the articular surfaces and give ease to the gliding movements; to moderate the effects of great pressure and deaden the intensity of the shocks to which the parts may be subjected. Humphry has pointed out that these interarticular fibrocartilages serve an important purpose in increasing the varieties of movement in a joint. Thus in the knee joint there are two kinds of motion, viz., angular movement and rotation, although it is a hinge joint, in which, as a rule, only one variety of motion is permitted; the former movement takes place between the condyles of the femur and the interarticular cartilages, the latter between the cartilages and the head of the tibia. So, also, in the temporomandibular joint, the movements of opening and shutting the mouth take place between the fibrocartilage and the mandible, the grinding movement between the mandibular fossa and the fibrocartilage, the latter moving with the mandible. *12*

2. The **Connecting Fibrocartilages** are interposed between the bony surfaces of those joints which admit of only slight mobility, as between the bodies of the vertebræ. They form disks which are closely adherent to the opposed surfaces. Each disk is composed of concentric rings of fibrous tissue, with cartilaginous laminæ interposed, the former tissue predominating toward the circumference, the latter toward the center. *13*

3. The **Circumferential Fibrocartilages** consist of rims of fibrocartilage, which surround the margins of some of the articular cavities, *e. g.,* the glenoidal labrum of the hip, and of the shoulder; they serve to deepen the articular cavities and to protect their edges. *14*

4. The **Stratiform Fibrocartilages** are those which form a thin coating to osseous grooves through which the tendons of certain muscles glide. Small masses of fibrocartilage are also developed in the tendons of some muscles, where they glide over bones, as in the tendons of the *15*

Peronæus longus and Tibialis posterior.

The distinguishing feature of cartilage chemically is that it yields on boiling a substance called **chondrin,** very similar to gelatin, but differing from it in several of its reactions. It is now believed that chondrin is not a simple body, but a mixture of gelatin with mucinoid substances, chief among which, perhaps, is a compound termed **chondro-mucoid.** *16*

Ligaments.—Ligaments are composed mainly of bundles of **white fibrous tissue** placed parallel with, or closely interlaced with one another, and present a white, shining, silvery appearance. They are pliant and flexible, so as to allow perfect freedom of movement, but strong, tough, and inextensible, so as not to yield readily to applied force. Some ligaments consist entirely of **yellow elastic tissue,** as the ligamenta flava which connect together the laminæ of adjacent vertebræ, and the ligamentum nuchæ in the lower animals. In these cases the elasticity of the ligament is intended to act as a substitute for muscular power. *17*

The Articular Capsules.—The articular capsules form complete envelopes for the freely movable joints. Each capsule consists of two strata—an **external** (*stratum fibrosum*) composed of white fibrous tissue, and an **internal** (*stratum synoviale*) which is a secreting layer, and is usually described separately as the synovial membrane. *18*

The **fibrous capsule** is attached to the whole circumference of the articular end of each bone entering into the joint, and thus entirely surrounds the articulation. *19*

The **synovial membrane** invests the inner surface of the fibrous capsule, and is reflected over any tendons passing through the joint cavity, as the tendon of the Popliteus in the knee, and the tendon of the Biceps brachii in the shoulder. It is composed of a thin, delicate, connective tissue, with branched connective-tissue corpuscles. Its secretion is thick, viscid, and glairy, like the white of an egg, and is hence termed **synovia.** In the fetus this membrane is said, by Toynbee, to be continued over the surfaces of the cartilages; but in the adult such a continuation is wanting, excepting at the circumference of the cartilage, upon which it encroaches for a short distance and to which it is firmly attached. In some of the joints the synovial membrane is thrown into folds which pass across the cavity; they are especially distinct in the knee. In other joints there are flattened folds, subdivided at their margins into fringe-like processes which contain convoluted vessels. These folds generally project from the synovial membrane near the margin of the cartilage, and lie flat upon its surface. They consist of connective tissue, covered with endothelium, and contain fat cells in variable quantities, and, more rarely, isolated cartilage cells; the larger folds often contain considerable quantities of fat. *20*

Closely associated with synovial membrane, and therefore conveniently described in this section, are the mucous sheaths of tendons and the mucous bursæ. *21*

Mucous sheaths (*vaginæ mucosæ*) serve to facilitate the gliding of tendons in fibroösseous canals. Each sheath is arranged in the form of an elongated closed sac, one layer of which adheres to the wall of the canal, and the other is reflected upon the surface of the enclosed tendon. These sheaths are chiefly found surrounding the tendons of the Flexor and Extensor muscles of the fingers and toes as they pass through fibroösseous canals in or near the hand and foot. *22*

Bursæ mucosæ are interposed between surfaces which glide upon each other. They consist of closed sacs containing a minute quantity of clear viscid fluid, and may be grouped, according to their situations, under the headings *subcutaneous, submuscular, subfacial,* and *subtendinous* *23*

2. Development of the Joints

The mesoderm from which the different parts of the skeleton are formed shows at first no differentiation into masses corresponding with the individual bones. Thus continuous cores of mesoderm form the axes of the limb-buds and a continuous column of mesoderm the future vertebral column. The first indications of the bones and joints are circumscribed condensations of the mesoderm; these condensed parts become chondrified and finally ossified to form the bones of the skeleton. The intervening non-condensed portions consist at first of undifferentiated mesoderm, which may develop in one of three directions. It may be converted into fibrous tissue as in the case of the skull bones, a synarthrodial joint being the result, or it may become partly cartilaginous, in which case an amphiarthrodial joint is formed. Again, it may become looser in texture and a cavity ultimately appear in its midst; the cells lining the sides of this cavity form a synovial membrane and thus a diarthrodial joint is developed. *1*

The tissue surrounding the original mesodermal core forms fibrous sheaths for the developing bones, *i. e.,* periosteum and perichondrium, which are continued between the ends of the bones over the synovial membrane as the capsules of the joints. These capsules are not of uniform thickness, so that in them may be recognized especially strengthened bands which are described as ligaments. This, however, is not the only method of formation of ligaments. In some cases by modification of, or derivations from, the tendons surrounding the joint, additional ligamentous bands are provided to further strengthen the articulations. *2*

In several of the movable joints the mesoderm which originally existed between the ends of the bones does not become completely absorbed—a portion of it persists and forms an articular disk. These disks may be intimately associated in their development with the muscles surrounding the joint, *e. g.,* the menisci of the knee-joint, or with cartilaginous elements, representatives of skeletal structures, which are vestigial in human anatomy, *e. g.,*the articular disk of the sternoclavicular joint.

3. Classification of Joints

The articulations are divided into three classes: **synarthroses** or immovable,**amphiarthroses** or slightly movable, and **diarthroses** or freely movable, joints. *1*

Synarthroses (*immovable articulations*).—Synarthroses include all those articulations in which the surfaces of the bones are in almost direct contact, fastened together by intervening connective tissue or hyaline cartilage, and in which there is no appreciable motion, as in the joints between the bones of the skull, excepting those of the mandible. There are four varieties of synarthrosis: **sutura, schindylesis, gomphosis,** and**synchondrosis.** *2*

Sutura.—Sutura is that form of articulation where the contiguous margins of the bones are united by a thin layer of fibrous tissue; it is met with only in the skull (Fig. 296). When the margins of the bones are connected by a series of processes, and indentations interlocked together, the articulation is termed a **true suture** (*sutura vera*); and of this there are three varieties: sutura dentata, serrata, and limbosa. The margins of the *3*

bones are not in direct contact, being separated by a thin layer of fibrous tissue, continuous externally with the pericranium, internally with the dura mater. The **sutura dentata** is so called from the tooth-like form of the projecting processes, as in the suture between the parietal bones. In the**sutura serrata** the edges of the bones are serrated like the teeth of a fine saw, as between the two portions of the frontal bone. In the **sutura limbosa,** there is besides the interlocking, a certain degree of bevelling of the articular surfaces, so that the bones overlap one another, as in the suture between the parietal and frontal bones. When the articulation is formed by roughened surfaces placed in apposition with one another, it is termed a **false suture** (*sutura notha*), of which there are two kinds: the **sutura squamosa,** formed by the overlapping of contiguous bones by broad bevelled margins, as in the squamosal suture between the temporal and parietal, and the **sutura harmonia,** where there is simple apposition of contiguous rough surfaces, as in the articulation between the maxillæ, or between the horizontal parts of the palatine bones.

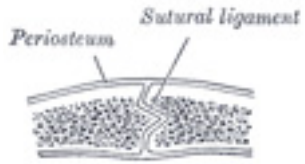

FIG. 296– Section across the sagittal suture. (See enlarged image)

FIG. 297– Section through occipitosphenoid synchondrosis of an infant. (See enlarged image)

Schindylesis.—Schindylesis is that form of articulation in which a thin plate of bone is received into a cleft or fissure formed by the separation of two laminæ in another bone, as in the articulation of the rostrum of the sphenoid and perpendicular plate of the ethmoid with the vomer, or in the reception of the latter in the fissure between the maxillæ and between the palatine bones. 4

Gomphosis.—Gomphosis is articulation by the insertion of a conical process into a socket; this is not illustrated by any articulation between bones, properly so called, but is seen in the articulations of the roots of the teeth with the alveoli of the mandible and maxillæ. 5

Synchondrosis.—Where the connecting medium is cartilage the joint is termed a synchondrosis (Fig. 297). This is a temporary form of joint, for the cartilage is converted into bone before adult life. Such joints are found between the epiphyses and bodies of long bones, between the occipital and the sphenoid at, and for some years after, birth, and between the petrous portion of the temporal and the jugular process of the occipital. 6

Amphiarthroses (*slightly movable articulations*).

—In these articulations the contiguous bony surfaces are either connected by broad flattened disks of fibrocartilage, of a more or less complex structure, as in the articulations between the bodies of the vertebræ; or are united by an interosseous ligament, as in the inferior tibiofibular articulation. The first form is termed a **symphysis** (Fig. 298), the second a **syndesmosis.** 7

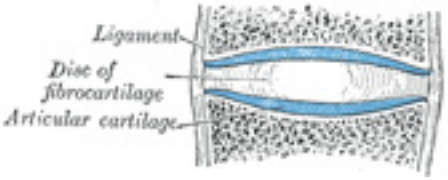

FIG. 298– Diagrammatic section of a symphysis. (See enlarged image)

Diarthroses (*freely movable articulations*).—This class includes the greater number of the joints in the body. In a diarthrodial joint the contiguous bony surfaces are covered with articular cartilage, and connected by ligaments lined by synovial membrane (Fig. 299). The joint may be divided, completely or incompletely, by an **articular disk** or **meniscus,** the periphery of which is continuous with the fibrous capsule while its free surfaces are covered by synovial membrane (Fig. 300). 8

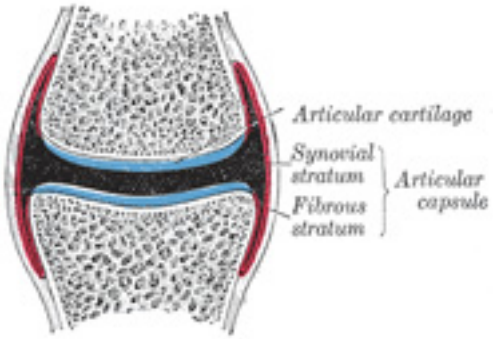

FIG. 299– Diagrammatic section of a diarthrodial joint. (See enlarged image)

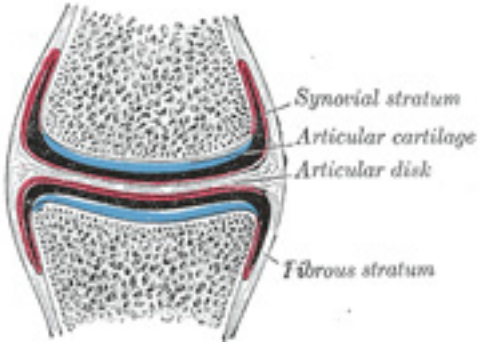

FIG. 300– Diagrammatic section of a diarthrodial joint, with an articular disk. (See enlarged image)

The varieties of joints in this class have been determined by the kind of motion permitted in each. There are two varieties in which the movement is uniaxial, that is to say, all movements take place around one axis. In one form, the **ginglymus,** this axis is, practically speaking, transverse; in the other, the **trochoid** or **pivot-joint,** it is longitudinal. There are two varieties where the movement is biaxial, or around two horizontal axes at right angles to each other, or at any intervening axis between the two. These are the **condyloid** and the**saddle-joint.** There is one form where the movement is polyaxial, the **enarthrosis** or **ball-and-socket joint;** and finally there are the **arthrodia** or **gliding joints.**

Ginglymus or Hinge-joint.—In this form the articular surfaces are moulded to each other in such a manner as to permit motion only in one plane, forward and backward, the extent of motion at the same time being considerable. The direction which the distal bone takes in this motion is seldom in the same plane as that of the axis of the proximal bone; there is usually a certain amount of deviation from the straight line during flexion. The articular surfaces are connected together by strong collateral ligaments, which form their chief bond of union. The best examples of ginglymus are the interphalangeal joints and the joint between the humerus and ulna; the knee- and ankle-joints are less typical, as they allow a slight degree of rotation or of side-to-side movement in certain positions of the limb. *10*

Trochoid or Pivot-joint (*articulatio trochoidea; rotary joint*).—Where the movement is limited to rotation, the joint is formed by a pivot-like process turning within a ring, or a ring on a pivot, the ring being formed partly of bone, partly of ligament. In the proximal radioulnar articulation, the ring is formed by the radial notch of the ulna and the annular ligament; here, the head of the radius rotates within the ring. In the articulation of the odontoid process of the axis with the atlas the ring is formed in front by the anterior arch, and behind by the transverse ligament of the atlas; here, the ring rotates around the odontoid process. *11*

Condyloid Articulation (*articulatio ellipsoidea*).—In this form of joint, an ovoid articular surface, or condyle, is received into an elliptical cavity in such a manner as to permit of flexion, extension, adduction, abduction, and circumduction, but no axial rotation. The wrist-joint is an example of this form of articulation. *12*

Articulation by Reciprocal Reception (*articulatio sellaris; saddle-joint*).—In this variety the opposing surfaces are reciprocally concavo-convex. The movements are the same as in the preceding form; that is to say, flexion, extension, adduction, abduction, and circumduction are allowed; but no axial rotation. The best example of this form is the carpometacarpal joint of the thumb. *13*

Enarthrosis (*ball-and-socket joints*).—Enarthrosis is a joint in which the distal bone is capable of motion around an indefinite number of axes, which have one common center. It is formed by the reception of a globular head into a cup-like cavity, hence the name "ball-and-socket." Examples of this form of articulation are found in the hip and shoulder. *14*

Arthrodia (*gliding joints*) is a joint which admits of only gliding movement; it is formed by the apposition of plane surfaces, or one slightly concave, the other slightly convex, the amount of motion between them being limited by the ligaments or osseous processes surrounding the articulation. It is the form present in the joints between the articular processes of the vertebræ, the carpal joints, except that of the capitate with the navicular and lunate, and the tarsal joints with the exception of that between the talus and the navicular.

4. The Kind of Movement Admitted in Joints

The movements admissible in joints may be divided into four kinds: **gliding** and **angular movements, circumduction,** and **rotation.** These movements are often, however, more or less combined in the various joints, so as to produce an infinite variety, and it is seldom that only one *1*

kind of motion is found in any particular joint.

Gliding Movement.—Gliding movement is the simplest kind of motion that can take place in a joint, one surface gliding or moving over another without any angular or rotatory movement. It is common to all movable joints; but in some, as in most of the articulations of the carpus and tarsus, it is the only motion permitted. This movement is not confined to plane surfaces, but may exist between any two contiguous surfaces, of whatever form. *2*

Angular Movement.—Angular movement occurs only between the long bones, and by it the angle between the two bones is increased or diminished. It may take place: (1) forward and backward, constituting flexion and extension; or (2) toward and from the median plane of the body, or, in the case of the fingers or toes, from the middle line of the hand or foot, constituting adduction and abduction. The strictly ginglymoid or hinge-joints admit of flexion and extension only. Abduction and adduction, combined with flexion and extension, are met with in the more movable joints; as in the hip, the shoulder, the wrist, and the carpometacarpal joint of the thumb. *3*

Circumduction.—Circumduction is that form of motion which takes place between the head of a bone and its articular cavity, when the bone is made to circumscribe a conical space; the base of the cone is described by the distal end of the bone, the apex is in the articular cavity; this kind of motion is best seen in the shoulder and hip-joints. *4*

Rotation.—Rotation is a form of movement in which a bone moves around a central axis without undergoing any displacement from this axis; the axis of rotation may lie in a separate bone, as in the case of the pivot formed by the odontoid process of the axis vertebræ around which the atlas turns; or a bone may rotate around its own longitudinal axis, as in the rotation of the humerus at the shoulder-joint; or the axis of rotation may not be quite parallel to the long axis of the bone, as in the movement of the radius on the ulna during pronation and supination of the hand, where it is represented by a line connecting the center of the head of the radius above with the center of the head of the ulna below. *5*

Ligamentous Action of Muscles.—The movements of the different joints of a limb are combined by means of the long muscles passing over more than one joint. These, when relaxed and stretched to their greatest extent, act as elastic ligaments in restraining certain movements of one joint, except when combined with corresponding movements of the other—the latter movements being usually in the opposite direction. Thus the shortness of the hamstring muscles prevents complete flexion of the hip, unless the knee-joint is also flexed so as to bring their attachments nearer together. The uses of this arrangement are threefold: (1) It coördinates the kinds of movements which are the most habitual and necessary, and enables them to be performed with the least expenditure of power. (2) It enables the short muscles which pass over only one joint to act upon more than one. (3) It provides the joints with ligaments which, while they are of very great power in resisting movements to an extent incompatible with the mechanism of the joint, at the same time spontaneously yield when necessary. *6*

The articulations may be grouped into those of the trunk, and those of the upper and lower extremities.

5. Articulations of the Trunk. a. Articulations of the Vertebral Column

These may be divided into the following groups, viz.: 1

I. Of the Vertebral Column.
II. Of the Atlas with the Axis.
III. Of the Vertebral Column with the Cranium.
IV. Of the Mandible.
V. Of the Ribs with the Vertebræ.
VI. Of the Cartilages of the Ribs with the Sternum, and with Each Other.
VII. Of the Sternum.
VIII. Of the Vertebral Column with the Pelvis.
IX. Of the Pelvis.

2

Articulations of the Vertebral Column

The articulations of the vertebral column consist of (1) a series of amphiarthrodial joints between the vertebral bodies, and (2) a series of diathrodial joints between the vertebral arches.

1. Articulations of Vertebral Bodies (*intercentral ligaments*).—The articulations between the bodies of the vertebræ are amphiarthrodial joints, and the individual vertebræ move only slightly on each other. When, however, this slight degree of movement between the pairs of bones takes place in all the joints of the vertebral column, the total range of movement is very considerable. The ligaments of these articulations are the following: 3

The Anterior Longitudinal. The Posterior Longitudinal.
The Intervertebral Fibrocartilages.

The Anterior Longitudinal Ligament (*ligamentum longitudinale anterius; anterior common ligament*) (Figs. 301, 312).—The anterior longitudinal ligament is a broad and strong band of fibers, which extends along the anterior surfaces of the bodies of the vertebræ, from the axis to the sacrum. It is broader below than above, thicker in the thoracic than in the cervical and lumbar regions, and somewhat thicker opposite the bodies of the vertebræ than opposite the intervertebral fibrocartilages. It is attached, above, to the body of the axis, where it is continuous with the anterior atlantoaxial ligament, and extends down as far as the upper part of the front of the sacrum. It consists of dense longitudinal fibers, which are intimately adherent to the intervertebral fibrocartilages and the prominent margins of the vertebræ, but not to the middle parts of the bodies. In the latter situation the ligament is thick and serves to fill up the concavities on the anterior surfaces, and to make the front of the vertebral column more even. It is composed of several layers of fibers, which vary in length, but are closely interlaced with each other. The most superficial fibers are the longest and extend between four or five vertebræ. A second, subjacent set extends between two or three vertebræ while a third set, the shortest and deepest, reaches from one vertebra to the next. At the sides of the bodies the ligament consists of a few short fibers which pass from one vertebra to the next, separated from the concavities of the vertebral bodies by oval apertures for the passage of vessels. 4

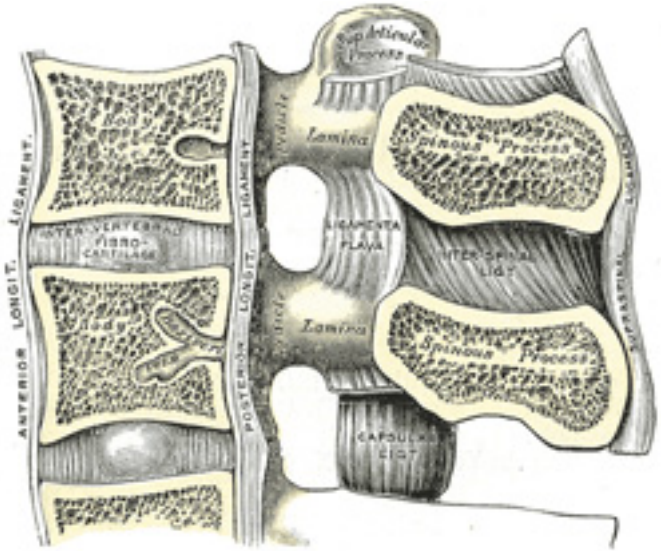

FIG. 301– Median sagittal section of two lumbar vertebræ and their ligaments. (See enlarged image)

The Posterior Longitudinal Ligament (*ligamentum longitudinale posterius; posterior common ligament*) (Figs. 301, 302).—The posterior longitudinal ligament is situated within the vertebral canal, and extends along the posterior surfaces of the bodies of the vertebræ, from the body of the axis, where it is continuous with the membrana tectoria, to the sacrum. It is broader above than below, and thicker in the thoracic than in the cervical and lumbar regions. In the situation of the intervertebral fibrocartilages and contiguous margins of the vertebræ, where the ligament is more intimately adherent, it is broad, and in the thoracic and lumbar regions presents a series of dentations with intervening concave margins; but it is narrow and thick over the centers of the bodies, from which it is separated by the basivertebral veins. This ligament is composed of smooth, shining, longitudinal fibers, denser and more compact than those of the anterior ligament, and consists of superficial layers occupying the interval between three or four vertebræ, and deeper layers which extend between adjacent vertebræ. 5

The Intervertebral Fibrocartilages (*fibrocartilagines intervertebrales; intervertebral disks*) (Figs. 301, 313).—The intervertebral fibrocartilages are interposed between the adjacent surfaces of the bodies of the vertebræ, from the axis to the sacrum, and form the chief bonds of connection between the vertebræ. They vary in shape, size, and thickness, in different parts of the vertebral column. In *shape* and *size* they correspond with the surfaces of the bodies between which they are placed, except in the cervical region, where they are slightly smaller from side to side than the corresponding bodies. In *thickness* they vary not only in the different regions of the column, but in different parts of the same 6

fibrocartilage; they are thicker in front than behind in the cervical and lumbar regions, and thus contribute to the anterior convexities of these parts of the column; while they are of nearly uniform thickness in the thoracic region, the anterior concavity of this part of the column being almost entirely owing to the shape of the vertebral bodies. The intervertebral fibrocartilages constitute about one-fourth of the length of the vertebral column, exclusive of the first two vertebræ; but this amount is not equally distributed between the various bones, the cervical and lumbar portions having, in proportion to their length, a much greater amount than the thoracic region, with the result that these parts possess greater pliancy and freedom of movement. The intervertebral fibrocartilages are adherent, by their surfaces, to thin layers of hyaline cartilage which cover the upper and under surfaces of the bodies of the vertebræ; in the lower cervical vertebræ, however, small joints lined by synovial membrane are occasionally present between the upper surfaces of the bodies and the margins of the fibrocartilages on either side. By their circumferences the intervertebral fibrocartilages are closely connected in front to the anterior, and behind to the posterior, longitudinal ligaments. In the thoracic region they are joined laterally, by means of the interarticular ligaments, to the heads of those ribs which articulate with two vertebræ.

FIG. 302– Posterior longitudinal ligament, in the thoracic region. (See enlarged image)

Structure of the Intervertebral Fibrocartilages.—Each is composed, at its circumference, of laminæ of fibrous tissue and fibrocartilage, forming the *annulus fibrosus;* and, at its center, of a soft, pulpy, highly elastic substance, of a yellowish color, which projects considerably above the surrounding level when the disk is divided horizontally. This pulpy substance (*nucleus pulposus*), especially well-developed in the lumbar region, is the remains of the notochord. The laminæ are arranged concentrically; the outermost consist of ordinary fibrous tissue, the others of white fibrocartilage. The laminæ are not quite vertical in their direction, those near the circumference being curved outward and closely approximated; while those nearest the center curve in the opposite direction, and are somewhat more widely separated. The fibers of which each lamina is composed are directed, for the most part, obliquely from above downward, the fibers of adjacent laminæ passing in opposite directions 7

and varying in every layer; so that the fibers of one layer are directed across those of another, like the limbs of the letter X. This laminar arrangement belongs to about the outer half of each fibrocartilage. The pulpy substance presents no such arrangement, and consists of a fine fibrous matrix, containing angular cells united to form a reticular structure.

The intervertebral fibrocartilages are important shock absorbers. Under pressure the highly elastic nucleus pulposus becomes flatter and broader and pushes the more resistant fibrous laminæ outward in all directions. *8*

2. Articulations of Vertebral Arches.—The joints between the articular processes of the vertebræ belong to the arthrodial variety and are enveloped by capsules lined by synovial membranes; while the laminæ, spinous and transverse processes are connected by the following ligaments: *9*

The Ligamenta Flava.	The Ligamentum Nuchæ.
The Supraspinal.	The Interspinal.
The Intertransverse.	

The Articular Capsules (*capsulæ articulares; capsular ligaments*) (Fig. 301).—The articular capsules are thin and loose, and are attached to the margins of the articular processes of adjacent vertebræ. They are longer and looser in the cervical than in the thoracic and lumbar regions. *10*

The Ligamenta Flava (*ligamenta subflava,* Fig. 303).—The ligamenta flava connect the laminæ of adjacent vertebræ, from the axis to the first segment of the sacrum. They are best seen from the interior of the vertebral canal; when looked at from the outer surface they appear short, being overlapped by the laminæ. Each ligament consists of two lateral portions which commence one on either side of the roots of the articular processes, and extend backward to the point where the laminæ meet to form the spinous process; the posterior margins of the two portions are in contact and to a certain extent united, slight intervals being left for the passage of small vessels. Each consists of yellow elastic tissue, the fibers of which, almost perpendicular in direction, are attached to the anterior surface of the lamina above, some distance from its inferior margin, and to the posterior surface and upper margin of the lamina below. In the cervical region the ligaments are thin, but broad and long; they are thicker in the thoracic region, and thickest in the lumbar region. Their marked elasticity serves to preserve the upright posture, and to assist the vertebral column in resuming it after flexion. *11*

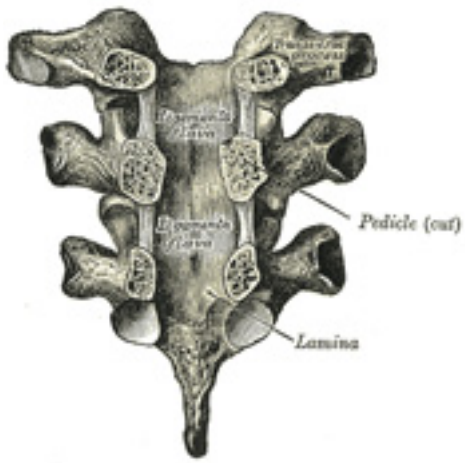

FIG. 303– Vertebral arches of three thoracic vertebræ viewed from the front. (See enlarged image)

The Supraspinal Ligament (***ligamentum supraspinale; supraspinous ligament***) **(Fig. 301).**—The supraspinal ligament is a strong fibrous cord, which connects together the apices of the spinous processes from the seventh cervical vertebra to the sacrum; at the points of attachment to the tips of the spinous processes fibrocartilage is developed in the ligament. It is thicker and broader in the lumbar than in the thoracic region, and intimately blended, in both situations, with the neighboring fascia. The most superficial fibers of this ligament extend over three or four vertebræ; those more deeply seated pass between two or three vertebræ while the deepest connect the spinous processes of neighboring vertebræ. Between the spinous processes it is continuous with the interspinal ligaments. It is continued upward to the external occipital protuberance and median nuchal line, as the ligamentum nuchæ. *12*

The Ligamentum Nuchæ.—The ligamentum nuchæ is a fibrous membrane, which, in the neck, represents the supraspinal ligaments of the lower vertebræ. It extends from the external occipital protuberance and median nuchal line to the spinous process of the seventh cervical vertebra. From its anterior border a fibrous lamina is given off, which is attached to the posterior tubercle of the atlas, and to the spinous processes of the cervical vertebræ, and forms a septum between the muscles on either side of the neck. In man it is merely the rudiment of an important elastic ligament, which, in some of the lower animals, serves to sustain the weight of the head. *13*

The Interspinal Ligaments (***ligamenta interspinalia; interspinous ligaments***) **(Fig. 301).**—The interspinal ligaments thin and membranous, connect adjoining spinous processes and extend from the root to the apex of each process. They meet the ligamenta flava in front and the *14*

supraspinal ligament behind. They are narrow and elongated in the thoracic region; broader, thicker, and quadrilateral in form in the lumbar region; and only slightly developed in the neck.

The Intertransverse Ligaments (*ligamenta intertransversaria*).—The intertransverse ligaments are interposed between the transverse processes. In the cervical region they consist of a few irregular, scattered fibers; in the thoracic region they are rounded cords intimately connected with the deep muscles of the back; in the lumbar region they are thin and membranous. *15*

Movements.—The movements permitted in the vertebral column are: *flexion, extension, lateral movement, circumduction,* and *rotation*. *16*

In **flexion,** or movement forward, the anterior longitudinal ligament is relaxed, and the intervertebral fibrocartilages are compressed in front; while the posterior longitudinal ligament, the ligamenta flava, and the inter- and supraspinal ligaments are stretched, as well as the posterior fibers of the intervertebral fibrocartilages. The interspaces between the laminæ are widened, and the inferior articular processes glide upward, upon the superior articular processes of the subjacent vertebræ. Flexion is the most extensive of all the movements of the vertebral column, and is freest in the lumbar region. *17*

In **extension,** or movement backward, an exactly opposite disposition of the parts takes place. This movement is limited by the anterior longitudinal ligament, and by the approximation of the spinous processes. It is freest in the cervical region. *18*

In **lateral movement,** the sides of the intervertebral fibrocartilages are compressed, the extent of motion being limited by the resistance offered by the surrounding ligaments. This movement may take place in any part of the column, but is freest in the cervical and lumbar regions. *19*

Circumduction is very limited, and is merely a succession of the preceding movements. *20*

Rotation is produced by the twisting of the intervertebral fibrocartilages; this, although only slight between any two vertebræ, allows of a considerable extent of movement when it takes place in the whole length of the column, the front of the upper part of the column being turned to one or other side. This movement occurs to a slight extent in the cervical region, is freer in the upper part of the thoracic region, and absent in the lumbar region. *21*

The extent and variety of the movements are influenced by the shape and direction of the articular surfaces. In the *cervical* region the upward inclination of the superior articular surfaces allows of free flexion and extension. Extension can be carried farther than flexion; at the upper end of the region it is checked by the locking of the posterior edges of the superior atlantal facets in the condyloid fossæ of the occipital bone; at the lower end it is limited by a mechanism whereby the inferior articular processes of the seventh cervical vertebra slip into grooves behind and below the superior articular processes of the first thoracic. Flexion is arrested just beyond the point where the cervical convexity is straightened; the movement is checked by the apposition of the projecting lower lips of the bodies of the vertebræ with the shelving surfaces on the bodies of the subjacent vertebræ. Lateral flexion and rotation are free in the cervical region; they are, however, always combined. The upward and medial inclinations of the superior articular surfaces impart a rotary movement during lateral flexion, while pure rotation is prevented by the slight medial slope of these surfaces. *22*

In the **thoracic region,** notably in its upper part, all the movements are limited in order to reduce interference with respiration to a minimum. The almost complete absence of an upward inclination of the superior articular surfaces prohibits any marked flexion, while extension is checked by the contact of the inferior articular margins with the laminæ, and the contact of the spinous processes with one another. The mechanism between the seventh cervical and the first thoracic vertebræ, which limits extension of the cervical region, will also serve to limit flexion of the *23*

thoracic region when the neck is extended. Rotation is free in the thoracic region: the superior articular processes are segments of a cylinder whose axis is in the mid-ventral line of the vertebral bodies. The direction of the articular facets would allow of free lateral flexion, but this movement is considerably limited in the upper part of the region by the resistance of the ribs and sternum.

In the **lumbar region** flexion and extension are free. Flexion can be carried farther than extension, and is possible to just beyond the straightening of the lumbar curve; it is, therefore, greatest at the lowest part where the curve is sharpest. The inferior articular facets are not in close apposition with the superior facets of the subjacent vertebræ, and on this account a considerable amount of lateral flexion is permitted. For the same reason a slight amount of rotation can be carried out, but this is so soon checked by the interlocking of the articular surfaces that it is negligible. *24*

The principal muscles which produce *flexion* are the Sternocleidomastoideus, Longus capitis, and Longus colli; the Scaleni; the abdominal muscles and the Psoas major.*Extension* is produced by the intrinsic muscles of the back, assisted in the neck by the Splenius, Semispinales dorsi and cervicis, and the Multifidus. *Lateral* motion is produced by the intrinsic muscles of the back by the Splenius, the Scaleni, the Quadratus lumborum, and the Psoas major, the muscles of one side only acting; and *rotation* by the action of the following muscles of one side only, viz., the Sternocleidomastoideus, the Longus capitis, the Scaleni, the Multifidus, the Semispinalis capitis, and the abdominal muscles.

5b. Articulation of the Atlas with the Epistropheus or Axis

(Articulatio Atlantoepistrophica) *1*

The articulation of the atlas with the axis is of a complicated nature, comprising no fewer than four distinct joints. There is a pivot articulation between the odontoid process of the axis and the ring formed by the anterior arch and the tranverse ligament of the atlas (see Fig. 306); here there are two joints: one between the posterior surface of the anterior arch of the atlas and the front of the odontoid process; the other between the anterior surface of the ligament and the back of the process. Between the articular processes of the two bones there is on either side an arthrodial or gliding joint. The ligaments connecting these bones are:

Two Articular Capsules.	The Posterior Atlantoaxial.
The Anterior Atlantoaxial.	The Transverse.

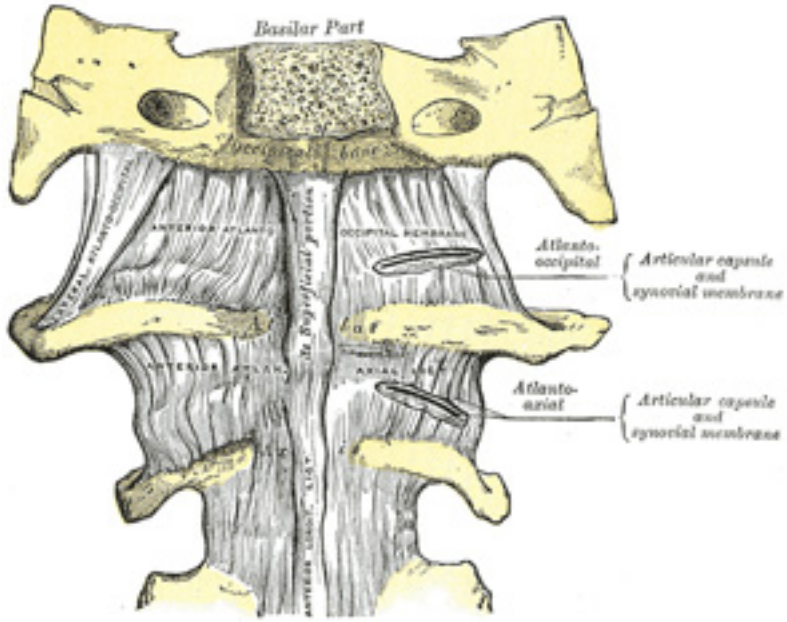

FIG. 304– Anterior atlantoöccipital membrane and atlantoaxial ligament. (See enlarged image)

The Articular Capsules (*capsulæ articulares; capsular ligaments*).—The articular capsules are thin and loose, and connect the margins of the lateral masses of the atlas with those of the posterior articular surfaces of the axis. Each is strengthened at its posterior and medial part by an **accessory ligament,** which is attached below to the body of the axis near the base of the odontoid process, and above to the lateral mass of the atlas near the transverse ligament. 2

The Anterior Atlantoaxial Ligament (Fig. 304).—This ligament is a strong membrane, fixed, *above,* to the lower border of the anterior arch of the atlas; *below,* to the front of the body of the axis. It is strengthened in the middle line by a rounded cord, which connects the tubercle on the anterior arch of the atlas to the body of the axis, and is a continuation upward of the anterior longitudinal ligament. The ligament is in relation, in front, with the Longi capitis. 3

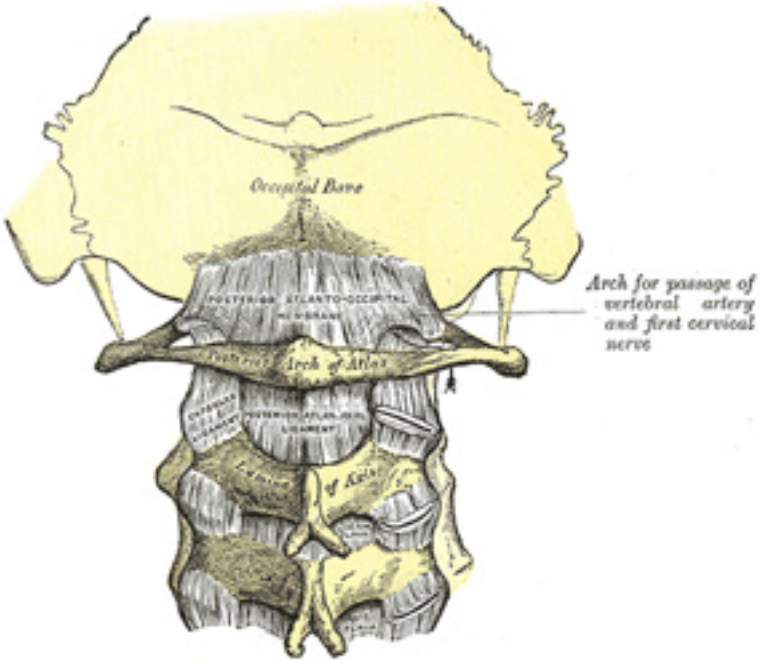

FIG. 305– Posterior atlantoöccipital membrane and atlantoaxial ligament. (See enlarged image)

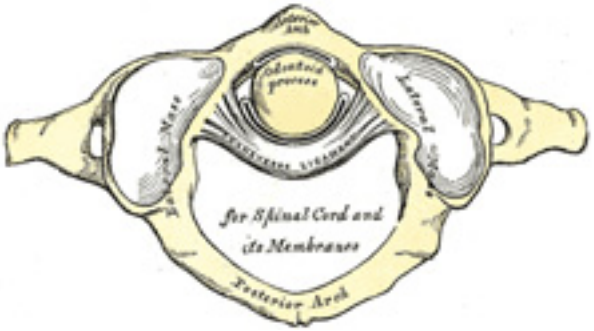

FIG. 306– Articulation between odontoid process and atlas. (See enlarged image)

The Posterior Atlantoaxial Ligament (Fig. 305).—This ligament is a broad, thin membrane attached, *above,* to the lower border of the posterior arch of the atlas; *below,* to the upper edges of the laminæ of the axis. It supplies the place of the ligamenta flava, and is in relation, *behind,* with the Obliqui capitis inferiores. 4

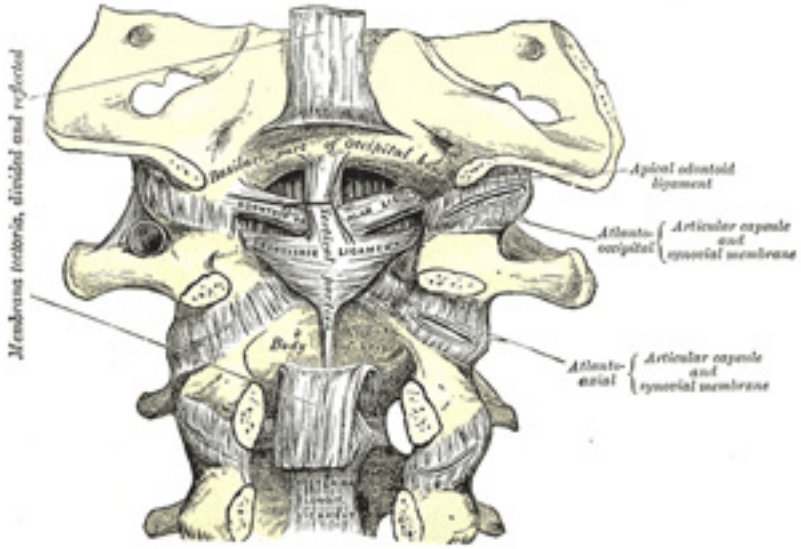

FIG. 307– Membrana tectoria, transverse, and alar ligaments. (See enlarged image)

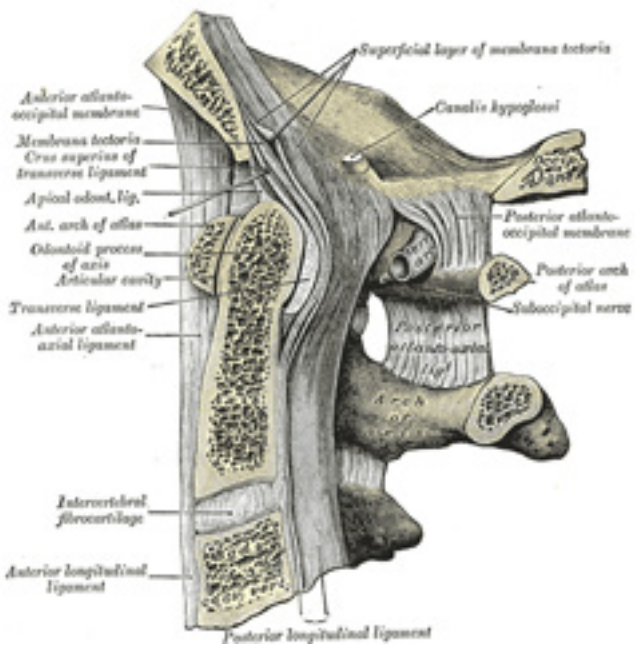

FIG. 308– Median sagittal section through the occipital bone and first three cervical vertebræ. (Spalteholz.) (See enlarged image)

The Transverse Ligament of the Atlas (*ligamentum transversum atlantis*) (Fig. 306,307, 308).—The transverse ligament of the atlas is a thick, strong band, which arches across the ring of the atlas, and retains the odontoid process in contact with the anterior arch. It is concave in front, convex behind, broader and thicker in the middle than at the ends, and firmly attached on either side to a small tubercle on the medial surface of the lateral mass of the atlas. As it crosses the odontoid process, a small fasciculus (*crus superius*) is prolonged upward, and another (*crus inferius*) downward, from the superficial or posterior fibers of the ligament. The former is attached to the basilar part of the occipital bone, in close relation with the membrana tectoria; the latter is fixed to the posterior surface of the body of the axis; hence, the whole ligament is named the **cruciate ligament of the atlas.** The transverse ligament divides the ring of the atlas into two unequal parts: of these, the posterior and larger serves for the transmission of the medulla spinalis and its membranes and the accessory nerves; the anterior and smaller contains the odontoid process. The neck of the odontoid process is constricted where it is embraced posteriorly by the transverse ligament, so that this ligament suffices to retain the odontoid process in position after all the other ligaments have been divided. 5

Synovial Membranes.—There is a synovial membrane for each of the four joints; the joint cavity between the odontoid process and the transverse ligament is often continuous with those of the atlantoöccipital articulations. 6

Movements.—The opposed articular surfaces of the atlas and axis are not reciprocally curved; both surfaces are convex in their long axes. When, therefore, the upper facet glides forward on the lower it also descends; the fibers of the articular capsule are relaxed in a vertical direction, and will then permit of movement in an antero-posterior direction. By this means a shorter capsule suffices and the strength of the joint is materially increased. 67 7

This joint allows the rotation of the atlas (and, with it, the skull) upon the axis, the extent of rotation being limited by the alar ligaments. 8

The principal muscles by which these movements are produced are the Sternocleidomastoideus and Semispinalis capitis of one side, acting with the Longus capitis, Splenius, Longissimus capitis, Rectus capitis posterior major, and Obliqui capitis superior and inferior of the other side. 9

Note 67. Corner ("The Physiology of the Atlanto-axial Joints," Journal of Anatomy and Physiology, vol. xli) states that the movements which take place at these articulations are of a complex nature. The first part of the movement is an eccentric or asymmetrical one; the atlanto-axial joint of the side to which the head is moved is fixed, or practically fixed, by the muscles of the neck, and forms the center of the movement, while the opposite atlantal facet is carried downward and forward on the corresponding axial facet. The second part of the movement is centric and symmetrical, the odontoid process forming the axis of the movement [back]

5c. Articulations of the Vertebral Column with the Cranium

The ligaments connecting the vertebral column with the cranium may be divided into two sets: those uniting the atlas with the occipital bone, and those connecting the axis with the occipital bone. 1

Articulation of the Atlas with the Occipital Bone (*articulatio atlantoöccipitalis*).—The articulation between the atlas and the occipital bone consists of a pair of condyloid joints. The ligaments connecting the bones are: 2

Two Articular Capsules.	The Posterior Atlantoöccipital membrane.
The Anterior Atlantoöccipital membrane.	Two Lateral Atlantoöccipital.

The Articular Capsules (*capsulæ articulares; capsular ligaments*).—The articular capsules surround the condyles of the occipital bone, and connect them with the articular processes of the atlas: they are thin and loose. 3

The Anterior Atlantoöccipital Membrane (*membrana atlantoöccipitalis anterior; anterior atlantoöccipital ligament*) (Fig. 304).—The anterior atlantoöccipitalis membrane is broad and composed of densely woven fibers, which pass between the anterior margin of the foramen magnum above, and the upper border of the anterior arch of the atlas below; laterally, it is continuous with the articular capsules; in front, it is 4

strengthened in the middle line by a strong, rounded cord, which connects the basilar part of the occipital bone to the tubercle on the anterior arch of the atlas. This membrane is in relation in *front* with the Recti capitis anteriores, *behind* with the alar ligaments.

The Posterior Atlantoöccipital Membrane (*membrana atlantoöccipitalis posterior; posterior atlantoöccipital ligament*) (Fig. 305).—The posterior atlantoöccipital membrane, broad but thin, is connected above, to the posterior margin of the foramen magnum; below, to the upper border of the posterior arch of the atlas. On either side this membrane is defective below, over the groove for the vertebral artery, and forms with this groove an opening for the entrance of the artery and the exit of the suboccipital nerve. The free border of the membrane, arching over the artery and nerve, is sometimes ossified. The membrane is in relation, *behind,* with the Recti capitis posteriores minores and Obliqui capitis superiores; in *front,* with the dura mater of the vertebral canal, to which it is intimately adherent. 5

The Lateral Ligaments.—The lateral ligaments are thickened portions of the articular capsules, reinforced by bundles of fibrous tissue, and are directed obliquely upward and medialward; they are attached above to the jugular processes of the occipital bone, and below, to the bases of the transverse processes of the atlas. 6

Synovial Membranes.—There are two synovial membranes: one lining each of the articular capsules. The joints frequently communicate with that between the posterior surface of the odontoid process and the transverse ligament of the atlas. 7

Movements.—The movements permitted in this joint are (*a*) flexion and extension, which give rise to the ordinary forward and backward nodding of the head, and (*b*) slight lateral motion to one or other side. *Flexion* is produced mainly by the action of the Longi capitis and Recti capitis anteriores; *extension* by the Recti capitis posteriores major and minor, the Obliquus superior, the Semispinalis capitis, Splenius capitis, Sternocleidomastoideus, and upper fibers of the Trapezius. The Recti laterales are concerned in the *lateral movement,*assisted by the Trapezius, Splenius capitis, Semispinalis capitis, and the Sternocleidomastoideus of the same side, all acting together. 8

Ligaments Connecting the Axis with the Occipital Bone.—

The Membrana Tectoria. Two Alar. The Apical Odontoid.

The Membrana Tectoria (*occipitoaxial ligament*) (Figs. 307, 308).—The membrana tectoria is situated within the vertebral canal. It is a broad, strong bands which covers the odontoid process and its ligaments, and appears to be a prolongation upward of the posterior longitudinal ligament of the vertebral column. It is fixed, below, to the posterior surface of the body of the axis, and, expanding as it ascends, is attached to the basilar groove of the occipital bone, in front of the foramen magnum, where it blends with the cranial dura mater. Its anterior surface is in relation with the transverse ligament of the atlas, and its posterior surface with the dura mater. 9

The Alar Ligaments (*ligamenta alaria; odontoid ligaments*) (Fig. 307).—The alar ligaments are strong, rounded cords, which arise one on 10

either side of the upper part of the odontoid process, and, passing obliquely upward and lateralward, are inserted into the rough depressions on the medial sides of the condyles of the occipital bone. In the triangular interval between these ligaments is another fibrous cord, the **apical odontoid ligament** (Fig. 308), which extends from the tip of the odontoid process to the anterior margin of the foramen magnum, being intimately blended with the deep portion of the anterior atlantoöccipital membrane and superior crus of the transverse ligament of the atlas. It is regarded as a rudimentary intervertebral fibrocartilage, and in it traces of the notochord may persist. The alar ligaments limit rotation of the cranium and therefore receive the name of **check ligaments.**

In addition to the ligaments which unite the atlas and axis to the skull, the ligamentum nuchæ (page 290) must be regarded as one of the ligaments connecting the vertebral column with the cranium.

5d. Articulation of the Mandible

(Articulatio Mandibularis; Temporomandibular Articulation) *1*

This is a ginglymo-arthrodial joint; the parts entering into its formation on either side are: the anterior part of the mandibular fossa of the temporal bone and the articular tubercle above; and the condyle of the mandible below. The ligaments of the joint are the following:

The Articular Capsule. The Sphenomandibular.
The Temporomandibular. The Articular Disk.
The Stylomandibular.

The Articular Capsule (*capsula articularis; capsular ligament*).—The articular capsule is a thin, loose envelope, attached above to the circumference of the mandibular fossa and the articular tubercle immediately in front; below, to the neck of the condyle of the mandible. *2*

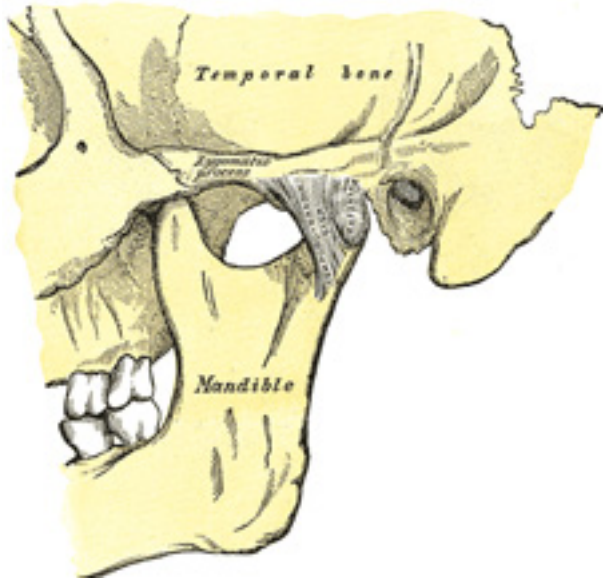

FIG. 309– Articulation of the mandible. Lateral aspect. (See enlarged image)

The Temporomandibular Ligament (***ligamentum temporomandibulare; external lateral ligament***) **(Fig. 309).**—The temporomandibular ligament consists of two short, narrow fasciculi, one in front of the other, attached, above, to the lateral surface of the zygomatic arch and to the tubercle on its lower border; below, to the lateral surface and posterior border of the neck of the mandible. It is broader above than below, and its fibers are directed obliquely downward and backward. It is covered by the parotid gland, and by the integument. 3

The Sphenomandibular Ligament (***ligamentum sphenomandibulare; internal lateral ligament***) **(Fig. 310).**—The sphenomandibular ligament is a flat, thin band which is attached above to the spina angularis of the sphenoid bone, and, becoming broader as it descends, is fixed to the lingula of the mandibular foramen. Its lateral surface is in relation, above, with the Pterygoideus externus; lower down, it is separated from the neck of the condyle by the internal maxillary vessels; still lower, the inferior alveolar vessels and nerve and a lobule of the parotid gland lie between it and the ramus of the mandible. Its medial surface is in relation with the Pterygoideus internus. 4

The Articular Disk (***discus articularis; interarticular fibrocartilage; articular meniscus***)**(Fig. 311).**—The articular disk is a thin, oval plate, 5

placed between the condyle of the mandible and the mandibular fossa. Its upper surface is concavo-convex from before backward, to accommodate itself to the form of the mandibular fossa and the articular tubercle. Its under surface, in contact with the condyle, is concave. Its circumference is connected to the articular capsule; and in front to the tendon of the Pterygoideus externus. It is thicker at its periphery, especially behind, than at its center. The fibers of which it is composed have a concentric arrangement, more apparent at the circumference than at the center. It divides the joint into two cavities, each of which is furnished with a synovial membrane.

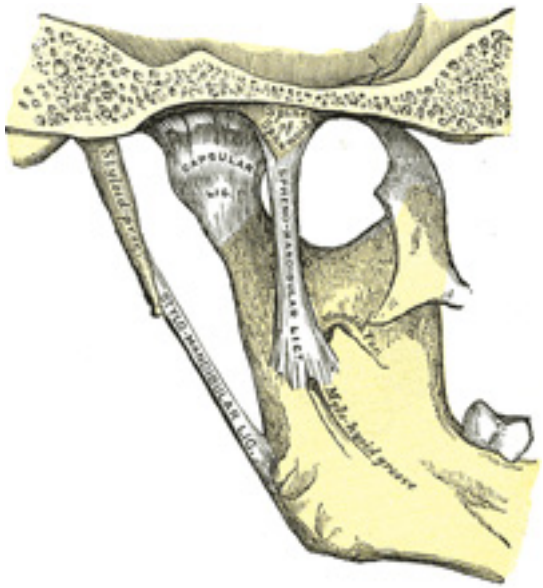

FIG. 310– Articulation of the mandible. Medial aspect. (See enlarged image)

FIG. 311– Sagittal section of the articulation of the mandible. (See enlarged image)

The Synovial Membranes.—The synovial membranes, two in number, are placed one above, and the other below, the articular disk. The upper one, the larger and looser of the two, is continued from the margin of the cartilage covering the mandibular fossa and articular tubercle on to the upper surface of the disk. The lower one passes from the under surface of the disk to the neck of the condyle, being prolonged a little farther downward behind than in front. The articular disk is sometimes perforated in its center, and the two cavities then communicate with each other. 6

The Stylomandibular Ligament (*ligamentum stylomandibulare*); *stylomaxillary ligament* (Fig. 310).—The stylomandibular ligament is a specialized band of the cervical fascia, which extends from near the apex of the styloid process of the temporal bone to the angle and posterior border of the ramus of the mandible, between the Masseter and Pterygoideus internus. This ligament separates the parotid from the submaxillary gland, and from its deep surface some fibers of the Styloglossus take origin. Although classed among the ligaments of the temporomandibular joint, it can only be considered as accessory to it. 7

The **nerves** of the temporomandibular joint are derived from the auriculotemporal and masseteric branches of the mandibular nerve, the **arteries** from the superficial temporal branch of the external carotid. 8

Movements.—The movements permitted in this articulation are extensive. Thus, the mandible may be depressed or elevated, or carried forward or backward; a slight amount of side-to-side movement is also permitted. It must be borne in mind that there are two distinct joints in this articulation—one between the condyle and the articular disk, and another between the disk and the mandibular fossa. When the mouth is but slightly opened, as during ordinary conversation, the movement is confined to the lower of the two joints. On the other hand, when the mouth is opened more widely, both joints are concerned in the movement; in the lower joint the movement is of a hinge-like character, the condyle moving around a transverse axis on the disk, while in the upper joint the movement is of a gliding character, the disk, together with the condyle, gliding forward on to the articular tubercle, around an axis which passes through the mandibular foramina. These two movements take place 9

simultaneously, the condyle and disk move forward on the eminence, and at the same time the condyle revolves on the disk. In shutting the mouth the reverse action takes place; the disk glides back, carrying the condyle with it, and this at the same time moves back to its former position. When the mandible is carried horizontally forward, as in protruding the lower incisor teeth in front of the upper, the movement takes place principally in the upper joint, the disk and the condyle gliding forward on the mandibular fossa and articular tubercle. The grinding or chewing movement is produced by one condyle, with its disk, gliding alternately forward and backward, while the other condyle moves simultaneously in the opposite direction; at the same time the condyle undergoes a vertical rotation on the disk. One condyle advances and rotates, the other condyle recedes and rotates, in alternate succession.

The mandible is *depressed* by its own weight, assisted by the Platysma, the Digastricus, the Mylohyoideus, and the Geniohyoideus. It is *elevated* by the Masseter, Pterygoideus internus, and the anterior part of the Temporalis. It is drawn *forward* by the simultaneous action of the Pterygoidei internus and externus, the superficial fibers of the Masseter and the anterior fibers of the Temporalis; and *backward* by the deep fibers of the Masseter and the posterior fibers of the Temporalis. The grinding movement is caused by the alternate action of the Pterygoidei of either side.

5e. Costovertebral Articulations

(Articulationes Costovertebrales) *1*

The articulations of the ribs with the vertebral column may be divided into two sets, one connecting the heads of the ribs with the bodies of the vertebræ, another uniting the necks and tubercles of the ribs with the transverse processes.

1. Articulations of the Heads of the Ribs (*articulationes capitulorum; costocentral articulations*) (Fig. 312).—These constitute a series of gliding or arthrodial joints, and are formed by the articulation of the heads of the typical ribs with the facets on the contiguous margins of the bodies of the thoracic vertebræ and with the intervertebral fibrocartilages between them; the first, tenth, eleventh, and twelfth ribs each articulate with a single vertebra. The ligaments of the joints are: *2*

The Articular Capsule. The Radiate. The Interarticular.

The Articular Capsule (*capsula articularis; capsular ligament*).—The articular capsule surrounds the joint, being composed of short, strong fibers, connecting the head of the rib with the circumference of the articular cavity formed by the intervertebral fibrocartilage and the adjacent vertebræ. It is most distinct at the upper and lower parts of the articulation; some of its upper fibers pass through the intervertebral foramen to the back of the intervertebral fibrocartilage, while its posterior fibers are continuous with the ligament of the neck of the rib. *3*

The Radiate Ligament (*ligamentum capituli costæ radiatum; anterior costovertebral or stellate ligament*).—The radiate ligament connects the anterior part of the head of each rib with the side of the bodies of two vertebræ, and the intervertebral fibrocartilage between them. It consists *4*

of three flat fasciculi, which are attached to the anterior part of the head of the rib, just beyond the articular surface. The superior fasciculus ascends and is connected with the body of the vertebra above; the inferior one descends to the body of the vertebra below; the middle one, the smallest and least distinct, is horizontal and is attached to the intervertebral fibrocartilage. The radiate ligament is in relation, in *front,* with the thoracic ganglia of the sympathetic trunk, the pleura, and, on the right side, with the azygos vein;*behind,* with the interarticular ligament and synovial membranes.

In the case of the first rib, this ligament is not divided into three fasciculi, but its fibers are attached to the body of the last cervical vertebra, as well as to that of the first thoracic. In the articulations of the heads of the tenth, eleventh, and twelfth ribs, each of which articulates with a single vertebra, the triradiate arrangement does not exist; but the fibers of the ligament in each case are connected to the vertebra above, as well as to that with which the rib articulates. *5*

The Interarticular Ligament (*ligamentum capituli costæ interarticulare*).—The interarticular ligament is situated in the interior of the joint. It consists of a short band of fibers, flattened from above downward, attached by one extremity to the crest separating the two articular facets on the head of the rib, and by the other to the intervertebral fibrocartilage; it divides the joint into two cavities. In the joints of the first, tenth, eleventh, and twelfth ribs, the interarticular ligament does not exist; consequently, there is but one cavity in each of these articulations. This ligament is the homologue of the **ligamentum conjugale** present in some mammals, and uniting the heads of opposite ribs, across the back of the intervertebral fibrocartilage. *6*

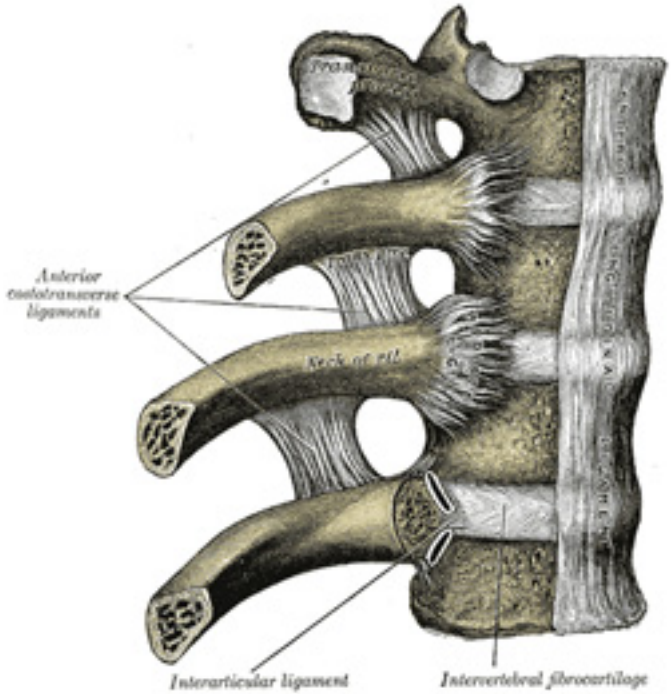

FIG. 312– Costovertebral articulations. Anterior view. (See enlarged image)

Synovial Membranes.—There are two synovial membranes in each of the articulations where an interarticular ligament exists, one above and one below this structure; but only one in those joints where there are single cavities. 7

2. Costotransverse Articulations (*articulationes costotransversariæ*) (Fig. 313).—The articular portion of the tubercle of the rib forms with the articular surface on the adjacent transverse process an arthrodial joint. 8

In the eleventh and twelfth ribs this articulation is wanting. 9

The ligaments of the joint are: 10

The Articular Capsule. The Posterior Costotransverse.

The Anterior Costotransverse. The Ligament of the Neck of the Rib.
The Ligament of the Tubercle of the Rib.

The Articular Capsule (*capsula articularis; capsular ligament*).—The articular capsule is a thin membrane attached to the circumferences of the articular surfaces, and lined by a synovial membrane. *11*

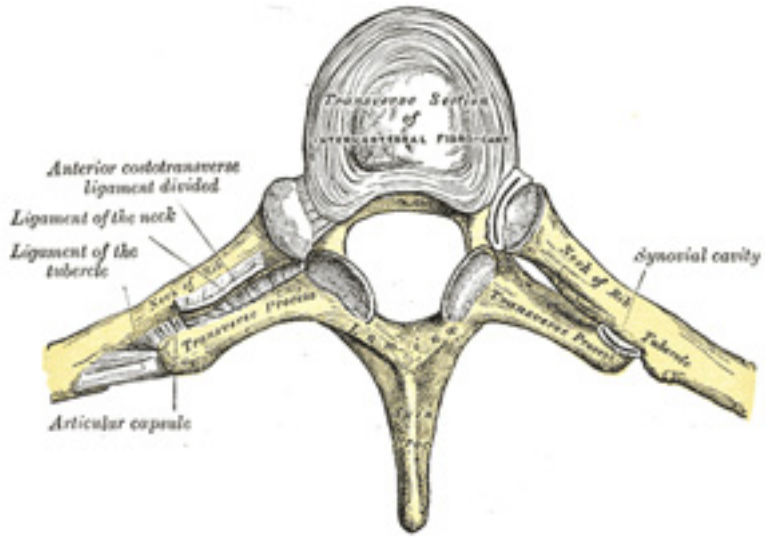

FIG. 313– Costotransverse articulation. Seen from above. (See enlarged image)

The Anterior Costotransverse Ligament (*ligamentum costotransversarium anterius; anterior superior ligament*).—The anterior costotransverse ligament is attached below to the sharp crest on the upper border of the neck of the rib, and passes obliquely upward and lateralward to the lower border of the transverse process immediately above. It is in relation, in front, with the intercostal vessels and nerves; its medial border is thickened and free, and bounds an aperture which transmits the posterior branches of the intercostal vessels and nerves; its lateral border is continuous with a thin aponeurosis, which covers the Intercostalis externus. *12*

The first rib has no anterior costotransverse ligament. A band of fibers, the **lumbocostal ligament,** in series with the anterior costotransverse ligaments, connects the neck of the twelfth rib to the base of the transverse process of the first lumbar vertebra; it is merely a thickened portion *13*

of the posterior layer of the lumbodorsal fascia.

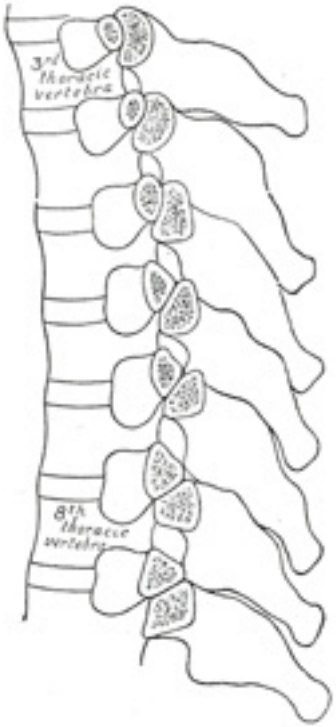

FIG. 314– Section of the costotransverse joints from the third to the ninth inclusive. Constrast the concave facets on the upper with the flattened facets on the lower transverse processes. (See enlarged image)

The Posterior Costotransverse Ligament (*ligamentum costotransversarium posterius*).—The posterior costotransverse ligament is a feeble band which is attached below to the neck of the rib and passes upward and medialward to the base of the transverse process and lateral border of the inferior articular process of the vertebra above. *14*

The Ligament of the Neck of the Rib (*ligamentum colli costæ middle costotransverse or interosseous ligament*).—The ligament of the neck *15*

of the rib consists of short but strong fibers, connecting the rough surface on the back of the neck of the rib with the anterior surface of the adjacent transverse process. A rudimentary ligament may be present in the case of the eleventh and twelfth ribs.

The Ligament of the Tubercle of the Rib (*ligamentum tuberculi costæ posterior costotransverse ligament*).—The ligament of the tubercle of the rib is a short but thick and strong fasciculus, which passes obliquely from the apex of the transverse process to the rough non-articular portion of the tubercle of the rib. The ligaments attached to the upper ribs ascend from the transverse processes; they are shorter and more oblique than those attached to the inferior ribs, which descend slightly. *16*

Movements.—The heads of the ribs are so closely connected to the bodies of the vertebræ by the radiate and interarticular ligaments that only slight gliding movements of the articular surfaces on one another can take place. Similarly, the strong ligaments binding the necks and tubercles of the ribs to the transverse processes limit the movements of the costotransverse joints to slight gliding, the nature of which is determined by the shape and direction of the articular surfaces (Fig. 314). In the upper six ribs the articular surfaces on the tubercles are oval in shape and convex from above downward; they fit into corresponding concavities on the *anterior surfaces* of the transverse processes, so that upward and downward movements of the tubercles are associated with rotation of the rib neck on its long axis. In the seventh, eighth, ninth, and tenth ribs the articular surfaces on the tubercles are flat, and are directed obliquely downward, medialward, and backward. The surfaces with which they articulate are placed on the *upper margins* of the transverse processes; when, therefore, the tubercles are drawn up they are at the same time carried backward and medialward. The two joints, costocentral and costotransverse, move simultaneously and in the same directions, the total effect being that the neck of the rib moves as if on a single joint, of which the costocentral and costotransverse articulations form the ends. In the upper six ribs the neck of the rib moves but slightly upward and downward; its chief movement is one of rotation around its own long axis, rotation backward being associated with depression, rotation forward with elevation. In the seventh, eighth, ninth, and tenth ribs the neck of the rib moves upward, backward, and medialward, or downward, forward, and lateralward; very slight rotation accompanies these movements.

1F. Sternocostal Articulations

(Articulationes Sternocotales; Costosternal Articulations) (Fig. 315) *1*

The articulations of the cartilages of the true ribs with the sternum are arthrodial joints, with the exception of the first, in which the cartilage is directly united with the sternum, and which is, therefore, a synarthrodial articulation. The ligaments connecting them are:

The Articular Capsules.	The Interarticular Sternocostal.
The Radiate Sternocostal.	The Costoxiphoid.

The Articular Capsules (*capsulæ articulares; capsular ligaments*).—The articular capsules surround the joints between the cartilages of the *2*

true ribs and the sternum. They are very thin, intimately blended with the radiate sternocostal ligaments, and strengthened at the upper and lower parts of the articulations by a few fibers, which connect the cartilages to the side of the sternum.

The Radiate Sternocostal Ligaments (*ligamenta sternocostalia radiata; chondrosternal or sternocostal ligaments*).—These ligaments consist of broad and thin membranous bands that radiate from the front and back of the sternal ends of the cartilages of the true ribs to the anterior and posterior surfaces of the sternum. They are composed of fasciculi which pass in different directions. The **superior fasciculi** ascend obliquely, the **inferior fasciculi** descend obliquely, and the **middle fasciculi** run horizontally. The superficial fibers are the longest; they intermingle with the fibers of the ligaments above and below them, with those of the opposite side, and in front with the tendinous fibers of origin of the Pectoralis major, forming a thick fibrous membrane (**membrana sterni**) which envelopes the sternum. This is more distinct at the lower than at the upper part of the bone. *3*

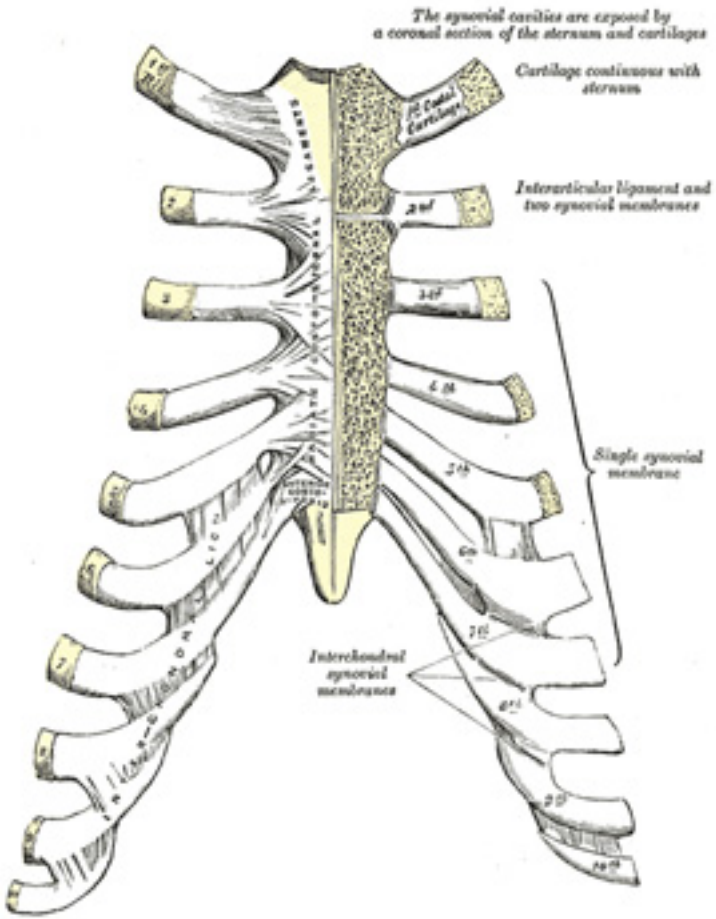

FIG. 315– Sternocostal and interchondral articulations. Anterior view. (See enlarged image)

The Interarticular Sternocostal Ligament (*ligamentum sternocostale interarticulare; interarticular chondrosternal ligament*).—This ligament is found constantly only between the second costal cartilages and the sternum. The cartilage of the *second rib* is connected with the

sternum by means of an interarticular ligament, attached by one end to the cartilage of the rib, and by the other to the fibrocartilage which unites the manubrium and body of the sternum. This articulation is provided with two synovial membranes. Occasionally the cartilage of the *third rib* is connected with the first and second pieces of the body of the sternum by an interarticular ligament. Still more rarely, similar ligaments are found in the other four joints of the series. In the lower two the ligament sometimes completely obliterates the cavity, so as to convert the articulation into an amphiarthrosis.

The Costoxiphoid Ligaments (*ligamenta costoxiphoidea; chondroxiphoid ligaments*).—These ligaments connect the anterior and posterior surfaces of the seventh costal cartilage, and sometimes those of the sixth, to the front and back of the xiphoid process. They vary in length and breadth in different subjects; those on the back of the joint are less distinct than those in front. *5*

Synovial Membranes.—There is no synovial membrane between the first costal cartilage and the sternum, as this cartilage is directly continuous with the manubrium. There are two in the articulation of the second costal cartilage and generally one in each of the other joints; but those of the sixth and seventh sternocostal joints are sometimes absent; where an interarticular ligament is present, there are two synovial cavities. After middle life the articular surfaces lose their polish, become roughened, and the synovial membranes apparently disappear. In old age, the cartilages of most of the ribs become continuous with the sternum, and the joint cavities are consequently obliterated. *6*

Movements.—Slight gliding movements are permitted in the sternocostal articulations. *7*

Interchondral Articulations (*articulationes interchondrales; articulations of the cartilages of the ribs with each other*) (Fig. 315).—The contiguous borders of the sixth, seventh, and eighth, and sometimes those of the ninth and tenth, costal cartilages articulate with each other by small, smooth, oblong facets. Each articulation is enclosed in a thin**articular capsule,** lined by **synovial membrane** and strengthened laterally and medially by ligamentous fibers (**interchondral ligaments**) which pass from one cartilage to the other. Sometimes the fifth costal cartilages, more rarely the ninth and tenth, articulate by their lower borders with the adjoining cartilages by small oval facets; more frequently the connection is by a few ligamentous fibers. *8*

Costochondral Articulations.—The lateral end of each costal cartilage is received into a depression in the sternal end of the rib, and the two are held together by the periosteum.

5g. Articulation of the Manubrium and Body of the Sternum

The manubrium is united to the body of the sternum either by an amphiarthrodial joint—a piece of fibrocartilage connecting the segments—or by a diarthrodial joint, in which the articular surface of each bone is clothed with a lamina of cartilage. In the latter case, the cartilage covering the body is continued without interruption on to the cartilages of the facets for the second ribs. Rivington found the diarthrodial form of joint in about one-third of the specimens examined by him, Maisonneuve more frequently. It appears to be rare in childhood, and is formed, in Rivington's *1*

opinion, from the amphiarthrodial form, by absorption. The diarthrodial joint seems to have no tendency to ossify, while the amphiarthrodial is more liable to do so, and has been found ossified as early as thirty-four years of age. The two segments are further connected by **anterior** and **posterior intersternal ligaments** consisting of longitudinal fibers.

Mechanism of the Thorax.—Each rib possesses its own range and variety of movements, but the movements of all are combined in the respiratory excursions of the thorax. Each rib may be regarded as a lever the fulcrum of which is situated immediately outside the costotransverse articulation, so that when the body of the rib is elevated the neck is depressed and *vice versa;* from the disproportion in length of the arms of the lever a slight movement at the vertebral end of the rib is greatly magnified at the anterior extremity. 2

The anterior ends of the ribs lie on a lower plane than the posterior; when therefore the body of the rib is elevated the anterior extremity is thrust also forward. Again, the middle of the body of the rib lies in a plane below that passing through the two extremities, so that when the body is elevated relatively to its ends it is at the same time carried outward from the median plane of the thorax. Further, each rib forms the segment of a curve which is greater than that of the rib immediately above, and therefore the elevation of a rib increases the transverse diameter of the thorax in the plane to which it is raised. The modifications of the rib movements at their vertebral ends have already been described (page 302). Further modifications result from the attachments of their anterior extremities, and it is convenient therefore to consider separately the movements of the ribs of the three groups—vertebrosternal, vertebrochondral, and vertebral. 3

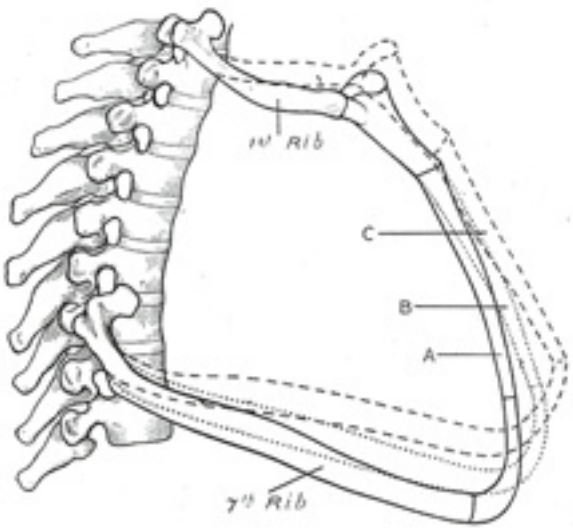

FIG. 316– Lateral view of first and seventh ribs in position, showing the movements of the sternum and ribs in *A,* ordinary expiration; *B,* quiet

inspiration; *C*, deep inspiration. (See enlarged image)

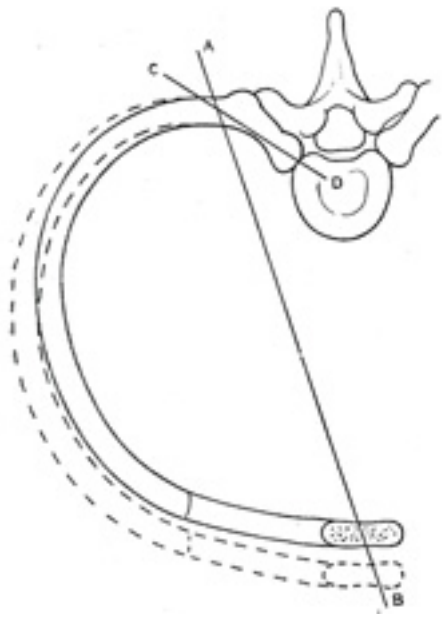

FIG. 317– Diagram showing the axes of movement (*A B* and *C D*) of a vertebrosternal rib. The interrupted lines indicate the position of the rib in inspiration. (See enlarged image)

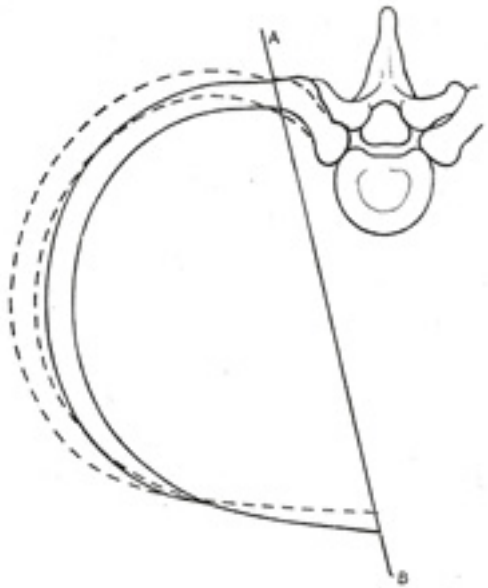

FIG. 318– Diagram showing the axis of movement (*A B*) of a vertebrochondral rib. The interrupted lines indicate the position of the rib in inspiration. (See enlarged image)

Vertebrosternal Ribs (Figs. 316, 317).—The first rib differs from the others of this group in that its attachment to the sternum is a rigid one; this is counterbalanced to some extent by the fact that its head possesses no interarticular ligament, and is therefore more movable. The first pair of ribs with the manubrium sterni move as a single piece, the anterior portion being elevated by rotatory movements at the vertebral extremities. In normal quiet respiration the movement of this arc is practically *nil;* when it does occur the anterior part is raised and carried forward, increasing the antero-posterior and transverse diameters of this region of the chest. The movement of the second rib is also slight in normal respiration, as its anterior extremity is fixed to the manubrium, and prevented therefore from moving upward. The sternocostal articulation, however, allows the middle of the body of the rib to be drawn up, and in this way the transverse thoracic diameter is increased. Elevation of the third, fourth, fifth, and sixth ribs raises and thrusts forward their anterior extremities, the greater part of the movement being effected by the rotation of the rib neck backward. The thrust of the anterior extremities carries forward and upward the body of the sternum, which moves on the joint between it and the manubrium, and thus the antero-posterior thoracic diameter is increased. This movement is, however, soon arrested, and the elevating force is then expended in raising the middle part of the body of the rib and everting its lower border; at the same time the costochondral angle is opened out. By these latter movements a considerable increase in the transverse diameter of the thorax is effected. 4

Vertebrochondral Ribs (Fig. 318).—The seventh rib is included with this group, as it conforms more closely to their type. While the movements of these ribs assist in enlarging the thorax for respiratory purposes, they are also concerned in increasing the upper abdominal space for viscera displaced by the action of the diaphragm. The costal cartilages articulate with one another, so that each pushes up that above it, the final thrust being directed to pushing forward and upward the lower end of the body of the sternum. The amount of elevation of the anterior extremities is limited on account of the very slight rotation of the rib neck. Elevation of the shaft is accompanied by an outward and backward movement; the outward movement everts the anterior end of the rib and opens up the subcostal angle, while the backward movement pulls back the anterior extremity and counteracts the forward thrust due to its elevation; this latter is most noticeable in the lower ribs, which are the shortest. The total result is a considerable increase in the transverse and a diminution in the median antero-posterior diameter of the upper part of the abdomen; at the same time, however, the lateral antero-posterior diameters of the abdomen are increased. 5

Vertebral Ribs.—Since these ribs have free anterior extremities and only costocentral articulations with no interarticular ligaments, they are capable of slight movements in all directions. When the other ribs are elevated these are depressed and fixed to form points of action for the diaphragm.

5h. Articulation of the Vertebral Column with the Pelvis The Iliolumbar Ligament

The ligaments connecting the fifth lumbar vertebra with the sacrum are similar to those which join the movable segments of the vertebral column with each other—viz.: 1. The continuation downward of the anterior and posterior longitudinal ligaments. 2. The intervertebral fibrocartilage, connecting the body of the fifth lumbar to that of the first sacral vertebra and forming an amphiarthrodial joint. 3. Ligamenta flava, uniting the laminæ of the fifth lumbar vertebra with those of the first sacral. 4. Capsules connecting the articular processes and forming a double arthrodia. 5. Inter- and supraspinal ligaments. 1

On either side an additional ligament, the **iliolumbar,** connects the pelvis with the vertebral column. 2

The Iliolumbar Ligament (*ligamentum iliolumbale*) (Fig. 319).—The iliolumbar ligament is attached above to the lower and front part of the transverse process of the fifth lumbar vertebra. It radiates as it passes lateralward and is attached by two main bands to the pelvis. The lower bands run to the base of the sacrum, blending with the anterior sacroiliac ligament; the upper is attached to the crest of the ilium immediately in front of the sacroiliac articulation, and is continuous above with the lumbodorsal fascia. In *front,* it is in relation with the Psoas major; *behind,* with the muscles occupying the vertebral groove; *above,* with the Quadratus lumborum.

5i. Articulations of the Pelvis

The ligaments connecting the bones of the pelvis with each other may be divided into four groups: 1. Those connecting the sacrum and ilium. 2. Those passing between the sacrum and ischium. 3. Those uniting the sacrum and coccyx. 4. Those between the two public bones. 1

1. Sacroiliac Articulation (*articulatio sacroiliaca*).—The sacroiliac articulation is an amphiarthrodial joint, formed between the auricular 2

surfaces of the sacrum and the ilium. The articular surface of each bone is covered with a thin plate of cartilage, thicker on the sacrum than on the ilium. These cartilaginous plates are in close contact with each other, and to a certain extent are united together by irregular patches of softer fibrocartilage, and at their upper and posterior part by fine interosseous fibers. In a considerable part of their extent, especially in advanced life, they are separated by a space containing a synovia-like fluid, and hence the joint presents the characteristics of a diarthrosis. The ligaments of the joint are:

The Anterior Sacroiliac. The Posterior Sacroiliac.

The Interosseous.

The Anterior Sacroiliac Ligament (*ligamentum sacroiliacum anterius*) (Fig. 319).—The anterior sacroiliac ligament consists of numerous thin bands, which connect the anterior surface of the lateral part of the sacrum to the margin of the auricular surface of the ilium and to the preauricular sulcus. *3*

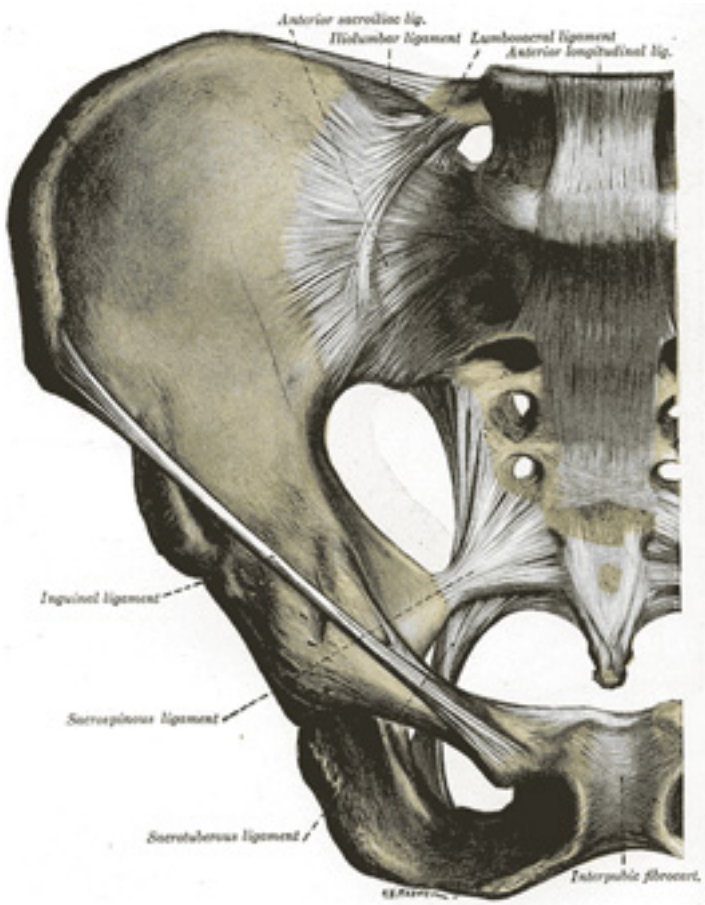

FIG. 319– Articulations of pelvis. Anterior view. (Quain.) (See enlarged image)

The Posterior Sacroiliac Ligament (*ligamentum sacroiliacum posterius*) (Fig. 320).—The posterior sacroiliac ligament is situated in a deep depression between the sacrum and ilium behind; it is strong and forms the chief bond of union between the bones. It consists of numerous fasciculi, which pass between the bones in various directions. The upper part (**short posterior sacroiliac ligament**) is nearly horizontal in

direction, and passs from the first and second transverse tubercles on the back of the sacrum to the tuberosity of the ilium. The lower part (**long posterior sacroiliac ligament**) is obique in direction; it is attached by one extremity to the third transverse tubercle of he back of the sacrum, and by the other to the posterior superior spine of the ilium.

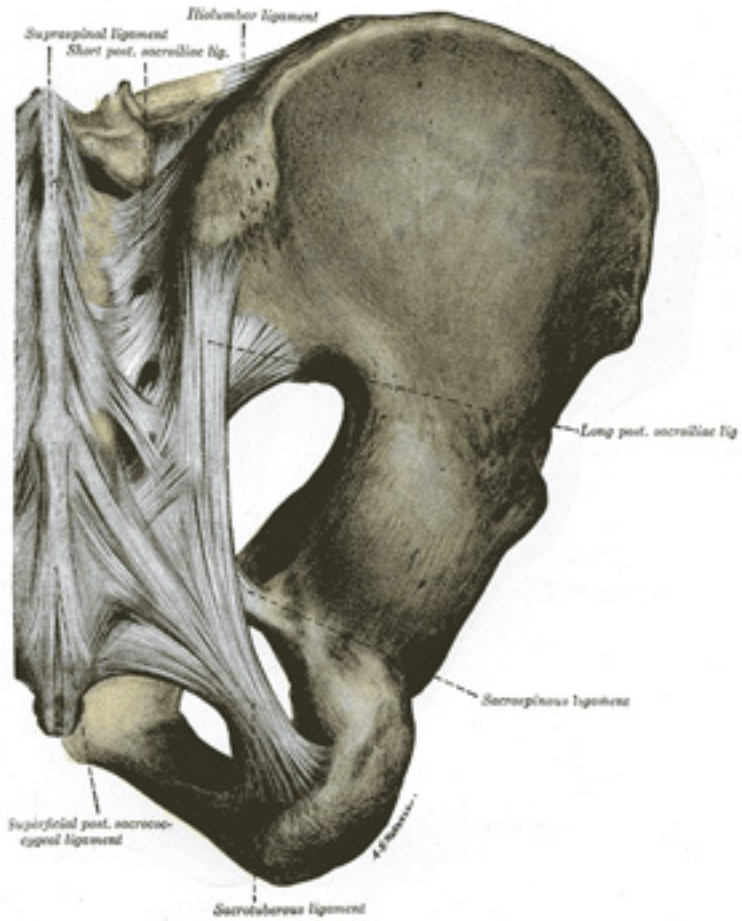

FIG. 320– Articulatios of pelvis. Posterior view. (Quain.) (See enlarged image)

The Interosseous Sacroiliac Ligament (*ligamentum sacroiliacum interosseum*).—This ligament lies deep to the poserior ligament, and consists of a series of short, strong fibers connecting the tubeosities of the sacrum and ilium. 5

2. Ligaments Connecting the Sacrum and Ischium (Fig. 320). 6

The Sacrotuberous. The Sacrospinous.

The Sacrotuberous Ligament (*ligamentum sacrotuberosum; great or posterior sacrosciatic ligament*).—The sacrotuberous ligament is situated at the lower and back part of the pelvis. It is flat, and triangular in form; narrower in the middle than at the ends; attached by its broad base to the posterior inferior spine of the ilium, to the fourth and fifth transverse tubercles of the sacrum, and to the lower part of the lateral margin of that bone and the coccyx. Passing obliquely downward, forward, and lateralward, it becomes narrow and thick, but at its insertion into the inner margin of the tuberosity of the ischium, it increases in breadth, and is prolonged forward along the inner margin of the ramus, as the**falciform process,** the free concave edge of which gives attachment to the obturator fascia; one of its surfaces is turned toward the perineum, the other toward the Obturator internus. The lower border of the ligament is directly continuous with the tendon of origin of the long head of the Biceps femoris, and by many is believed to be the proximal end of this tendon, cut off by the projection of the tuberosity of the ischium. 7

Relations.—The *posterior surface* of this ligament gives origin, by its whole extent, to the Glutæus maximus. Its *anterior surface* is in part united to the sacrospinous ligament. Its*upper border* forms, above, the posterior boundary of the greater sciatic foramen, and, below, the posterior boundary of the lesser sciatic foramen. Its *lower border* forms part of the boundary of the perineum. It is pierced by the coccygeal nerve and the coccygeal branch of the inferior gluteal artery. 8

The Sacrospinous Ligament (*ligamentum sacrospinosum; small or anterior sacrosciatic ligament*).—The sacrospinous ligament is thin, and triangular in form; it is attached by its apex to the spine of the ischium, and medially, by its broad base, to the lateral margins of the sacrum and coccyx, in front of the sacrotuberous ligament with which its fibers are intermingled. 9

Relations.—It is in relation, *anteriorly,* with the Coccygeus muscle, to which it is closely connected; *posteriorly,* it is covered by the sacrotuberous ligament, and crossed by the internal pudendal vessels and nerve. Its *upper border* forms the lower boundary of the greater sciatic foramen; its *lower border,* part of the margin of the lesser sciatic foramen. 10

These two ligaments convert the sciatic notches into foramina. The **greater sciatic foramen** is bounded, in *front* and *above,* by the posterior border of the hip bone; *behind,*by the sacrotuberous ligament; and *below,* by the sacrospinous ligament. It is partially filled up, in the recent state, by the Piriformis which leaves the pelvis through it. Above this muscle, the superior gluteal vessels and nerve emerge from the pelvis; and below it, the inferior gluteal vessels and nerve, the internal pudendal vessels and nerve, the sciatic and posterior femoral cutaneous nerves, and the nerves to the Obturator internus and Quadratus femoris make their exit from the pelvis. The **lesser sciatic foramen** is bounded, in *front,* by the tuberosity of the ischium; *above,* by the spine of the ischium and sacrospinous ligament;*behind,* by the sacrotuberous ligament. It transmits the 11

tendon of the Obturator internus, its nerve, and the internal pudendal vessels and nerve.

3. Sacrococcygeal Symphysis (*symphysis sacrococcygea; articulation of the sacrum and coccyx*).—This articulation is an amphiarthrodial joint, formed between the oval surface at the apex of the sacrum, and the base of the coccyx. It is homologous with the joints between the bodies of the vertebræ, and is connected by similar ligaments. They are: 12

The Anterior Sacrococcygeal.	The Posterior Sacrococcygeal.
The Lateral Sacrococcygeal.	The Interposed Fibrocartilage.

The Interarticular

The Anterior Sacrococcygeal Ligament (*ligamentum sacrococcygeum anterius*).—This consists of a few irregular fibers, which descend from the anterior surface of the sacrum to the front of the coccyx, blending with the periosteum. 13

The Posterior Sacrococcygeal Ligament (*ligamentum sacrococcygeum posterius*).—This is a flat band, which arises from the margin of the lower orifice of the sacral canal, and descends to be inserted into the posterior surface of the coccyx. This ligament completes the lower and back part of the sacral canal, and is divisible into a short deep portion and a longer superficial part. It is in relation, behind, with the Glutæus maximus. 14

The Lateral Sacrococcygeal Ligament (*ligamentum sacrococcygeum laterale; intertransverse ligament*).—The lateral sacrococcygeal ligament exists on either side and connects the transverse process of the coccyx to the lower lateral angle of the sacrum; it completes the foramen for the fifth sacral nerve. 15

A disk of **fibrocartilage** is interposed between the contiguous surfaces of the sacrum and coccyx; it differs from those between the bodies of the vertebræ in that it is thinner, and its central part is firmer in texture. It is somewhat thicker in front and behind than at the sides. Occasionally the coccyx is freely movable on the sacrum, most notably during pregnancy; in such cases a synovial membrane is present. 16

The **Interarticular Ligaments** are thin bands, which unite the cornua of the two bones. 17

The different segments of the coccyx are connected together by the extension downward of the anterior and posterior sacrococcygeal ligaments, thin annular disks of fibrocartilage being interposed between the segments. In the adult male, all the pieces become ossified together at a comparatively early period; but in the female, this does not commonly occur until a later period of life. At more advanced age the joint between the sacrum and coccyx is obliterated. 18

Movements.—The movements which take place between the sacrum and coccyx, and between the different pieces of the latter bone, are forward and backward; they are very limited. Their extent increases during pregnancy. 19

4. The Pubic Symphysis (*symphysis ossium pubis; articulation of the pubic bones*) (Fig. 321).—The articulation between the pubic bones is an amphiarthrodial joint, formed between the two oval articular surfaces of the bones. The ligaments of this articulation are: 20

The Anterior Pubic.	The Posterior Pubic.
The Superior Pubic.	The Arcuate Pubic.

The Anterior Pubic Ligament (Fig. 319).—The anterior pubic ligament consists of several superimposed layers, which pass across the front of the articulation. The superficial fibers pass obliquely from one bone to the other, decussating and forming an interlacement with the fibers of the aponeuroses of the Obliqui externi and the medial tendons of origin of the Recti abdominis. The deep fibers pass transversely across the symphysis, and are blended with the fibrocartilaginous lamina. *21*

The Posterior Pubic Ligament.—The posterior pubic ligament consists of a few thin, scattered fibers, which unite the two pubic bones posteriorly. *22*

The Superior Pubic Ligament (*ligamentum pubicum superius*).—The superior pubic ligament connects together the two pubic bones superiorly, extending laterally as far as the pubic tubercles. *23*

The Arcuate Pubic Ligament (*ligamentum arcuatum pubis; inferior pubic or subpubic ligament*).—The arcuate pubic ligament is a thick, triangular arch of ligamentous fibers, connecting together the two pubic bones below, and forming the upper boundary of the pubic arch. *Above,* it is blended with the interpubic fibrocartilaginous lamina; *laterally,* it is attached to the inferior rami of the pubic bones; *below,* it is free, and is separated from the fascia of the urogenital diaphragm by an opening through which the deep dorsal vein of the penis passes into the pelvis. *24*

The Interpubic Fibrocartilaginous Lamina (*lamina fibrocartilaginea interpubica; interpubic disk*).—The interpubic fibrocartilaginous lamina connects the opposed surfaces of the pubic bones. Each of these surfaces is covered by a thin layer of hyaline cartilage firmly joined to the bone by a series of nipple-like processes which accurately fit into corresponding depressions on the osseous surfaces. These opposed cartilaginous surfaces are connected together by an intermediate lamina of fibrocartilage which varies in thickness in different subjects. It often contains a cavity in its interior, probably formed by the softening and absorption of the fibrocartilage, since it rarely appears before the tenth year of life and is not lined by synovial membrane. This cavity is larger in the female than in the male, but it is very doubtful whether it enlarges, as was formerly supposed, during pregnancy. It is most frequently limited to the upper and back part of the joint; it occasionally reaches to the front, and may extend the entire length of the cartilage. It may be easily demonstrated when present by making a coronal section of the symphysis pubis near its posterior surface (Fig. 321). *25*

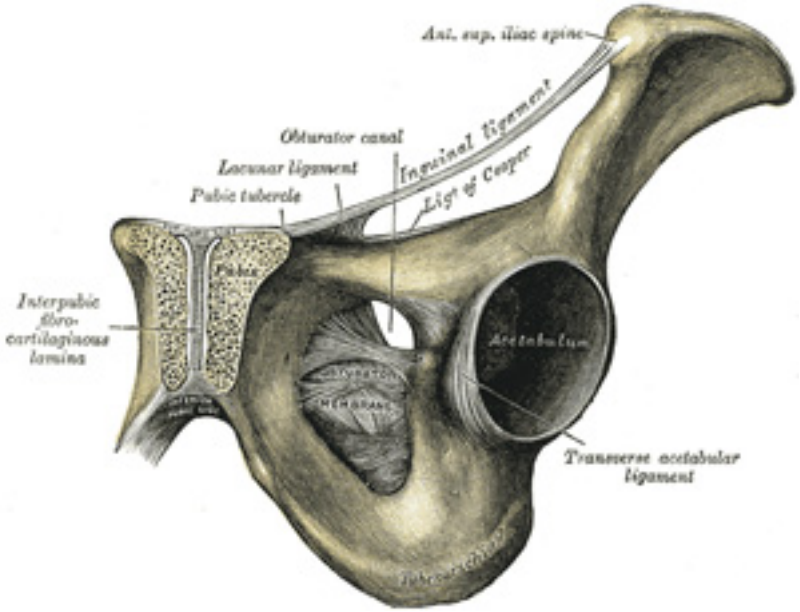

FIG. 321– Symphysis pubis exposed by a coronal section. (See enlarged image)

Mechanism of the Pelvis.—The pelvic girdle supports and protects the contained viscera and affords surfaces for the attachments of the trunk and lower limb muscles. Its most important mechanical function, however, is to transmit the weight of the trunk and upper limbs to the lower extremities. 26

It may be divided into two arches by a vertical plane passing through the acetabular cavities; the posterior of these arches is the one chiefly concerned in the function of transmitting the weight. Its essential parts are the upper three sacral vertebræ and two strong pillars of bone running from the sacroiliac articulations to the acetabular cavities. For the reception and diffusion of the weight each acetabular cavity is strengthened by two additional bars running toward the pubis and ischium. In order to lessen concussion in rapid changes of distribution of the weight, joints (sacroiliac articulations) are interposed between the sacrum and the iliac bones; an accessory joint (pubic symphysis) exists in the middle of the anterior arch. The sacrum forms the summit of the posterior arch; the weight transmitted falls on it at the lumbosacral articulation and, theoretically, has a component in each of two directions. One component of the force is expended in driving the sacrum downward and backward between the iliac bones, while the other thrusts the upper end of the sacrum downward and forward toward the pelvic cavity. 27

The movements of the sacrum are regulated by its form. Viewed as a whole, it presents the shape of a wedge with its base upward and forward. 28

The first component of the force is therefore acting against the resistance of the wedge, and its tendency to separate the iliac bones is resisted by the sacroiliac and iliolumbar ligaments and by the ligaments of the pubic symphysis.

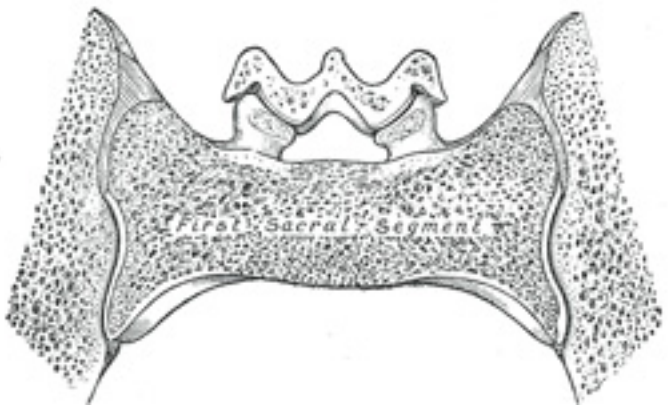

FIG. 322– Coronal section of anterior sacral segment. (See enlarged image)

FIG. 323– Coronal section of middle sacra segment. (See enlarged image)

If a series of coronal sections of the sacroiliac joints be made, it will be found possible to divide the articular portion of the sacrum into three segments: anterior, middle, and posterior. In the **anterior segment** (Fig. 322), which involves the first sacral vertebra, the articular surfaces show slight sinuosities and are almost parallel to one another; the distance between their dorsal margins is, however, slightly greater than that between their ventral margins. This segment therefore presents a slight wedge shape with the truncated apex downward. The **middle segment** (Fig. 323) is a narrow band across the centers of the articulations. Its dorsal width is distinctly greater than its ventral, so that the segment is more definitely wedge-shaped, the truncated apex being again directed downward. Each articular surface presents in the center a marked concavity from above downward, and into this a corresponding convexity of the iliac articular surface fits, forming an interlocking mechanism. In the **posterior segment** (Fig. 324) the ventral width is greater than the dorsal, so that the wedge form is the reverse of those of the other segments—*i. e.,* the truncated apex is directed upward. The articular surfaces are only slightly concave. 29

FIG. 324– Coronal section of posterior sacral segment. (See enlarged image)

Dislocation downward and forward of the sacrum by the second component of the force applied to it is prevented therefore by the middle segment, which interposes the resistance of its wedge shape and that of the interlocking mechanism on its surfaces; a rotatory movement, however, is produced by which the anterior segment is tilted downward and the posterior upward; the axis of this rotation passes through the dorsal part of the middle segment. The movement of the anterior segment is slightly limited by its wedge form, but chiefly by the posterior and interosseous sacroiliac ligaments; that of the posterior segment is checked to a slight extent by its wedge form, but the chief limiting factors are the sacrotuberous and sacrospinous ligaments. In all these movements the effect of the sacroiliac and iliolumbar ligaments and the ligaments of the symphysis pubis in resisting the separation of the iliac bones must be recognized. 30

During pregnancy the pelvic joints and ligaments are relaxed, and capable therefore of more extensive movements. When the fetus is being expelled the force is applied to the front of the sacrum. Upward dislocation is again prevented by the interlocking mechanism of the middle segment. As the fetal head passes the anterior segment the latter is carried upward, enlarging the antero-posterior diameter of the pelvic inlet; when the head reaches the posterior segment this also is pressed upward against the resistance of its wedge, the movement only being possible by the laxity of the joints and the stretching of the sacrotuberous and sacrospinous ligaments.

6. Articulations of the Upper Extremity. a. Sternoclavicular Articulation

The articulations of the Upper Extremity may be arranged as follows: 1

I. Sternoclavicular.	VI. Wrist.
II. Acromioclavicular.	VII. Intercarpal.
III. Shoulder.	VIII. Carpometacarpal.
IV. Elbow.	IX. Intermetacarpal.
V. Radioulnar.	X. Metacarpophalangeal.

XI. Articulations of the Digits.

2

Sternoclavicular Articulation (Articulatio Sternoclavicularis) (Fig. 325)

The sternoclavicular articulation is a double arthrodial joint. The parts entering into its formation are the sternal end of the clavicle, the upper and lateral part of the manubrium sterni, and the cartilage of the first rib. The articular surface of the clavicle is much larger than that of the sternum, and is invested with a layer of cartilage, 68 which is considerably thicker than that on the latter bone. The ligaments of this joint are:

The Articular Capsule.	The Interclavicular.
The Anterior Sternoclavicular.	The Costoclavicular.
The Posterior Sternoclavicular.	The Articular Disk.

The Articular Capsule (*capsula articularis; capsular ligament*).—The articular capsule surrounds the articulation and varies in thickness and strength. In front and behind it is of considerable thickness, and forms the anterior and posterior sternoclavicular ligaments; but above, and especially below, it is thin and partakes more of the character of areolar than of true fibrous tissue. 3

The Anterior Sternoclavicular Ligament (*ligamentum sternoclaviculare anterior*).—The anterior sternoclavicular ligament is a broad band of fibers, covering the anterior surface of the articulation; it is attached *above* to the upper and front part of the sternal end of the clavicle, and, passing obliquely downward and medialward, is attached below to the front of the upper part of the manubrium sterni. This ligament is covered by the sternal portion of the Sternocleidomastoideus and the integument; *behind,* it is in relation with the capsule, the articular disk, and the two synovial membranes. 4

The Posterior Sternoclavicular Ligament (*ligamentum sternoclaviculare posterius*).—The posterior sternoclavicular ligament is a similar band of fibers, covering the posterior surface of the articulation; it is attached above to the upper and back part of the sternal end of the clavicle, 5

and, passing obliquely downward and medialward, is fixed below to the back of the upper part of the manubrium sterni. It is in relation, in *front,* with the articular disk and synovial membranes; *behind,* with the Sternohyoideus and Sternothyreoideus.

The Interclavicular Ligament (*ligamentum interclaviculare*).—This ligament is a flattened band, which varies considerably in form and size in different individuals, it passes in a curved direction from the upper part of the sternal end of one clavicle to that of the other, and is also attached to the upper margin of the sternum. It is in relation, in *front,* with the integument and Sternocleidomastoidei; *behind,* with the Sternothyreoidei. 6

The Costoclavicular Ligament (*ligamentum costoclaviculare; rhomboid ligament*).—This ligament is short, flat, strong, and rhomboid in form. Attached below to the upper and medial part of the cartilage of the first rib, it ascends obliquely backward and lateralward, and is fixed above to the costal tuberosity on the under surface of the clavicle. It is in relation, in *front,* with the tendon of origin of the Subclavius; *behind,* with the subclavian vein. 7

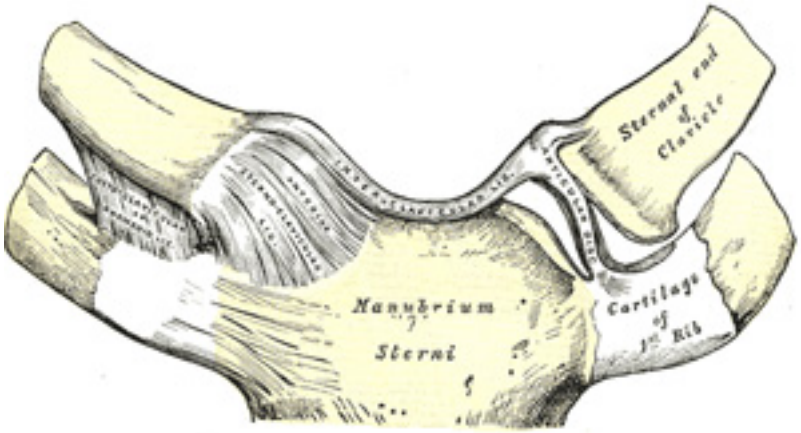

FIG. 325– Sternoclavicular articulation. Anterior view. (See enlarged image)

The Articular Disk (*discus articularis*).—The articular disk is flat and nearly circular, interposed between the articulating surfaces of the sternum and clavicle. It is attached,*above,* to the upper and posterior border of the articular surface of the clavicle; *below,* to the cartilage of the first rib, near its junction with the sternum; and by its circumference to the interclavicular and anterior and posterior sternoclavicular ligaments. It is thicker at the circumference, especially its upper and back part, than at its center. It divides the joint into two cavities, each of which is 8

furnished with a synovial membrane.

Synovial Membranes.—Of the two synovial membranes found in this articulation, the lateral is reflected from the sternal end of the clavicle, over the adjacent surface of the articular disk, and around the margin of the facet on the cartilage of the first rib; the medial is attached to the margin of the articular surface of the sternum and clothes the adjacent surface of the articular disk; the latter is the larger of the two. *9*

Movements.—This articulation admits of a limited amount of motion in nearly every direction—upward, downward, backward, forward, as well as circumduction. When these movements take place in the joint, the clavicle in its motion carries the scapula with it, this bone gliding on the outer surface of the chest. This joint therefore forms the center from which all movements of the supporting arch of the shoulder originate, and is the only point of articulation of the shoulder girdle with the trunk. The movements attendant on elevation and depression of the shoulder take place between the clavicle and the articular disk, the bone rotating upon the ligament on an axis drawn from before backward through its own articular facet; when the shoulder is moved forward and backward, the clavicle, with the articular disk rolls to and fro on the articular surface of the sternum, revolving, with a sliding movement, around an axis drawn nearly vertically through the sternum; in the circumduction of the shoulder, which is compounded of these two movements, the clavicle revolves upon the articular disk and the latter, with the clavicle, rolls upon the sternum. 69Elevation of the shoulder is limited principally by the costoclavicular ligament; depression, by the interclavicular ligament and articular disk. The muscles which *raise* the shoulder are the upper fibers of the Trapezius, the Levator scapulæ, and the clavicular head of the Sternocleidomastoideus, assisted to a certain extent by the Rhomboidei, which pull the vertebral border of the scapula backward and upward and so raise the shoulder. The*depression* of the shoulder is principally effected by gravity assisted by the Subclavius, Pectoralis minor and lower fibers of the Trapezius. The shoulder is drawn *backward* by the Rhomboidei and the middle and lower fibers of the Trapezius, and *forward* by the Serratus anterior and Pectoralis minor. *10*

Note 68. According to Bruch, the sternal end of the clavicle is covered by a tissue which is fibrous rather than cartilaginous in structure. [back]

Note 69. Humphry, On the Human Skeleton, page 402. [back]

6b. Acromioclavicular Articulation

Coracoacromial, Superior and Inferior Transverse.

(Articulatio Acromioclavicularis; Scapuloclavicular Articulation) (Fig. 326) *1*

The acromioclavicular articulation is an arthrodial joint between the acromial end of the clavicle and the medial margin of the acromion of the scapula. Its ligaments are:

The Articular Capsule. The Articular Disk.

The Superior Acromioclavicular.
The Coracoclavicular {Trapezoid and Conoid.
The Inferior Acromioclavicular.

The Articular Capsule (*capsula articularis; capsular ligament*).—The articular capsule completely surrounds the articular margins, and is strengthened above and below by the superior and inferior acromioclavicular ligaments. 2

The Superior Acromioclavicular Ligament (*ligamentum acromioclaviculare*).—This ligament is a quadrilateral band, covering the superior part of the articulation, and extending between the upper part of the acromial end of the clavicle and the adjoining part of the upper surface of the acromion. It is composed of parallel fibers, which interlace with the aponeuroses of the Trapezius and Deltoideus; *below,* it is in contact with the articular disk when this is present. 3

The Inferior Acromioclavicular Ligament.—This ligament is somewhat thinner than the preceding; it covers the under part of the articulation, and is attached to the adjoining surfaces of the two bones. It is in relation, *above,* in rare cases with the articular disk;*below,* with the tendon of the Supraspinatus. 4

The Articular Disk (*discus articularis*).—The articular disk is frequently absent in this articulation. When present, it generally only partially separates the articular surfaces, and occupies the upper part of the articulation. More rarely, it completely divides the joint into two cavities. 5

The Synovial Membrane.—There is usually only one synovial membrane in this articulation, but when a complete articular disk is present, there are two. 6

The Coracoclavicular Ligament (*ligamentum coracoclaviculare*) (Fig. 326).—This ligament serves to connect the clavicle with the coracoid process of the scapula. It does not properly belong to this articulation, but is usually described with it, since it forms a most efficient means of retaining the clavicle in contact with the acromion. It consists of two fasciculi, called the **trapezoid** and **conoid ligaments.** 7

The Trapezoid Ligament (*ligamentum trapezoideum*), the anterior and lateral fasciculus, is broad, thin, and quadrilateral: it is placed obliquely between the coracoid process and the clavicle. It is attached, *below,* to the upper surface of the coracoid process; *above,* to the oblique ridge on the under surface of the clavicle. Its anterior border is free; its posterior border is joined with the conoid ligament, the two forming, by their junction, an angle projecting backward. 8

The Conoid Ligament (*ligamentum conoideum*), the posterior and medial fasciculus, is a dense band of fibers, conical in form, with its base directed upward. It is attached by its apex to a rough impression at the base of the coracoid process, medial to the trapezoid ligament; above, by its expanded base, to the coracoid tuberosity on the under surface of the clavicle, and to a line proceeding medialward from it for 1.25 cm. These ligaments are in relation, in *front,* with the Subclavius and Deltoideus; *behind,* with the Trapezius. 9

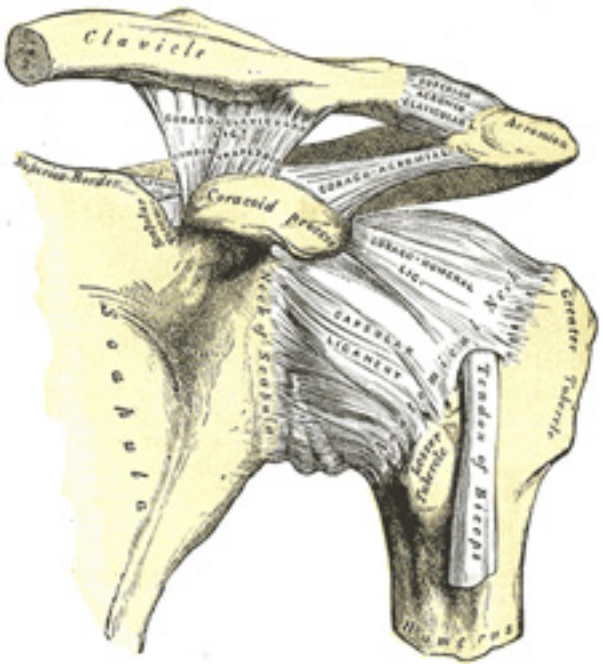

FIG. 326– The left shoulder and acromioclavicular joints, and the proper ligaments of the scapula. (See enlarged image)

Movements.—The movements of this articulation are of two kinds: (1) a gliding motion of the articular end of the clavicle on the acromion; (2) rotation of the scapula forward and backward upon the clavicle. The extent of this rotation is limited by the two portions of the coracoclavicular ligament, the trapezoid limiting rotation forward, and the conoid backward. *10*

The acromioclavicular joint has important functions in the movements of the upper extremity. It has been well pointed out by Humphry, that if there had been no joint between the clavicle and scapula, the circular movement of the scapula on the ribs (as in throwing the shoulders backward or forward) would have been attended with a greater alteration in the direction of the shoulder than is consistent with the free use of the arm in such positions, and it would have been impossible to give a blow straight forward with the full force of the arm; that is to say, with the combined force of the scapula, arm, and forearm. "This joint," as he happily says, "is so adjusted as to enable either bone to turn in a hinge-like manner upon a vertical axis drawn through the other, and it permits the surfaces of the scapula, like the baskets in a roundabout swing, to look *11*

the same way in every position, or nearly so." Again, when the whole arch formed by the clavicle and scapula rises and falls (in elevation or depression of the shoulder), the joint between these two bones enables the scapula still to maintain its lower part in contact with the ribs.

The Ligaments of the Scapula—The ligaments of the scapula (Fig. 326) are: *12*

The Coracoacromial Ligament (*ligamentum coracoaromiale*).—This ligament is a strong triangular band, extending between the coracoid process and the acromion. It is attached, by its apex, to the summit of the acromion just in front of the articular surface for the clavicle; and by its broad base to the whole length of the lateral border of the coracoid process. This ligament, together with the coracoid process and the acromion, forms a vault for the protection of the head of the humerus. It is in relation, *above,* with the clavicle and under surface of the Deltoideus; *below,* with the tendon of the Supraspinatus, a bursa being interposed. Its lateral border is continuous with a dense lamina that passes beneath the Deltoideus upon the tendons of the Supraspinatus and Infraspinatus. The ligament is sometimes described as consisting of two marginal bands and a thinner intervening portion, the two bands being attached respectively to the apex and the base of the coracoid process, and joining together at the acromion. When the Pectoralis minor is inserted, as occasionally is the case, into the capsule of the shoulder-joint instead of into the coracoid process, it passes between these two bands, and the intervening portion of the ligament is then deficient. *13*

The Superior Transverse Ligament (*ligamentum transversum scapulæ superius; transverse* or *suprascapular ligament*).—This ligament converts the scapular notch into a foramen. It is a thin and flat fasciculus, narrower at the middle than at the extremities, attached by one end to the base of the coracoid process, and by the other to the medial end of the scapular notch. The suprascapular nerve runs through the foramen; the transverse scapular vessels cross over the ligament. The ligament is sometimes ossified. *14*

The Inferior Transverse Ligament (*ligamentum transversum scapulæ inferius; spinoglenoid ligament*).—This ligament is a weak membranous band, situated behind the neck of the scapula and stretching from the lateral border of the spine to the margin of the glenoid cavity. It forms an arch under which the transverse scapular vessels and suprascapular nerve enter the infraspinatous fossa.

6c. Humeral Articulation or Shoulder-joint

(Articulatio Humeri) (Fig. 326) *1*

The shoulder-joint is an enarthrodial or ball-and-socket joint. The bones entering into its formation are the hemispherical head of the humerus and the shallow glenoid cavity of the scapula, an arrangement which permits of very considerable movement, while the joint itself is protected against displacement by the tendons which surround it. The ligaments do not maintain the joint surfaces in apposition, because when they alone remain the humerus can be separated to a considerable extent from the glenoid cavity; their use, therefore, is to limit the amount of movement. The joint is protected above by an arch, formed by the coracoid process, the acromion, and the coracoacromial ligament. The articular cartilage

on the head of the humerus is thicker at the center than at the circumference, the reverse being the case with the articular cartilage of the glenoid cavity. The ligaments of the shoulder are:

The Articular Capsule.	The Glenohumeral.
The Coracohumeral.	The Transverse Humeral.

The Glenoidal Labrum. 70

The Articular Capsule (*capsula articularis; capsular ligament*) (Fig. 327).—The articular capsule completely encircles the joint, being attached, above, to the circumference of the glenoid cavity beyond the glenoidal labrum; below, to the anatomical neck of the humerus, approaching nearer to the articular cartilage above than in the rest of its extent. It is thicker above and below than elsewhere, and is so remarkably loose and lax, that it has no action in keeping the bones in contact, but allows them to be separated from each other more than 2.5 cm., an evident provision for that extreme freedom of movement which is peculiar to this articulation. It is strengthened, *above,* by the Supraspinatus; *below,* by the long head of the Triceps brachii; *behind,* by the tendons of the Infraspinatus and Teres minor; and in *front,* by the tendon of the Subscapularis. There are usually three openings in the capsule. One anteriorly, below the coracoid process, establishes a communication between the joint and a bursa beneath the tendon of the Subscapularis. The second, which is not constant, is at the posterior part, where an opening sometimes exists between the joint and a bursal sac under the tendon of the Infraspinatus. The third is between the tubercles of the humerus, for the passage of the long tendon of the Biceps brachii. *2*

The Coracohumeral Ligament (*ligamentum coracohumerale*).—This ligament is a broad band which strengthens the upper part of the capsule. It arises from the lateral border of the coracoid process, and passes obliquely downward and lateralward to the front of the greater tubercle of the humerus, blending with the tendon of the Supraspinatus. This ligament is intimately united to the capsule by its hinder and lower border; but its anterior and upper border presents a free edge, which overlaps the capsule. *3*

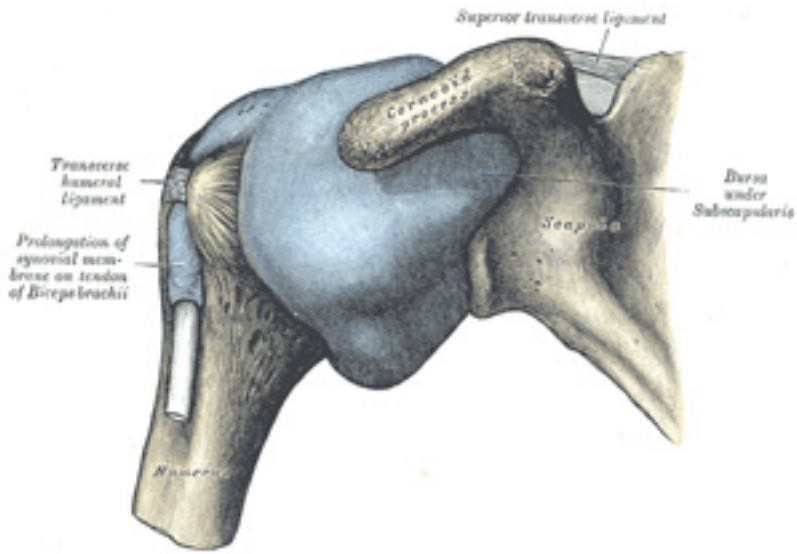

FIG. 327– Capsule of shoulder-joint (distended). Anterior aspect. (See enlarged image)

Glenohumeral Ligaments.—In addition to the coracohumeral ligament, three supplemental bands, which are named the **glenohumeral ligaments,** strengthen the capsule. These may be best seen by opening the capsule at the back of the joint and removing the head of the humerus. One on the medial side of the joint passes from the medial edge of the glenoid cavity to the lower part of the lesser tubercle of the humerus. A second at the lower part of the joint extends from the under edge of the glenoid cavity to the under part of the anatomical neck of the humerus. A third at the upper part of the joint is fixed above to the apex of the glenoid cavity close to the root of the coracoid process, and passing downward along the medial edge of the tendon of the Biceps brachii, is attached below to a small depression above the lesser tubercle of the humerus. In addition to these, the capsule is strengthened in front by two bands derived from the tendons of the Pectoralis major and Teres major respectively. *4*

The Transverse Humeral Ligament (Fig. 327) is a broad band passing from the lesser to the greater tubercle of the humerus, and always limited to that portion of the bone which lies above the epiphysial line. It converts the intertubercular groove into a canal, and is the homologue of the strong process of bone which connects the summits of the two tubercles in the musk ox. *5*

The Glenoidal Labrum (*labrium glenoidale; glenoid ligament*) is a fibrocartilaginous rim attached around the margin of the glenoid cavity. It is triangular on section, the base being fixed to the circumference of the cavity, while the free edge is thin and sharp. It is continuous above with the tendon of the long head of the Biceps brachii, which gives off two fasciculi to blend with the fibrous tissue of the labrum. It deepens the *6*

articular cavity, and protects the edges of the bone.

Synovial Membrane.—The synovial membrane is reflected from the margin of the glenoid cavity over the labrum; it is then reflected over the inner surface of the capsule, and covers the lower part and sides of the anatomical neck of the humerus as far as the articular cartilage on the head of the bone. The tendon of the long head of the Biceps brachii passes through the capsule and is enclosed in a tubular sheath of synovial membrane, which is reflected upon it from the summit of the glenoid cavity and is continued around the tendon into the intertubercular groove as far as the surgical neck of the humerus (Fig. 327). The tendon thus traverses the articulation, but it is not contained within the synovial cavity. 7

FIG. 328– Glenoid fossa of right side. (See enlarged image)

Bursæ.—The bursæ in the neighborhood of the shoulder-joint are the following: (1) A constant bursa is situated between the tendon of the Subscapularis muscle and the capsule; it communicates with the synovial cavity through an opening in the front of the capsule; (2) a bursa which occasionally communicates with the joint is sometimes found between the tendon of the Infraspinatus and the capsule; (3) a large bursa exists between the under surface of the Deltoideus and the capsule, but does not communicate with the joint; this bursa is prolonged under the acromion and coraco-acromial ligament, and intervenes between these structures and the capsule; (4) a large bursa is situated on the summit of the acromion; (5) a bursa is frequently found between the coracoid process and the capsule; (6) a bursa exists beneath the Coracobrachialis; (7) one lies between the Teres major and the long head of the Triceps brachii; (8) one is placed in front of, and another behind, the tendon of the Latissimus dorsi. 8

The **muscles** in relation with the joint are, *above,* the Supraspinatus; *below,* the long head of the Triceps brachii; in *front,* the Subscapularis; *behind,* the Infraspinatus and Teres minor; *within,* the tendon of the long head of the Biceps brachii. The Deltoideus covers the articulation in front, behind, and laterally. 9

The **arteries** supplying the joint are articular branches of the anterior and posterior humeral circumflex, and transverse scapular. 10

The **nerves** are derived from the axillary and suprascapular. 11

Movements.—The shoulder-joint is capable of every variety of movement, flexion, extension, abduction, adduction, circumduction, and rotation. The humerus is *flexed* (drawn forward) by the Pectoralis major, anterior fibers of the Deltoideus, Coracobrachialis, and when the forearm is flexed, by the Biceps brachii; *extended* (drawn backward) by the Latissimus dorsi, Teres major, posterior fibers of the Deltoideus, and, when the forearm is extended, by the Triceps brachii; it is *abducted* by the Deltoideus and Supraspinatus; it is*adducted* by the Subscapularis, Pectoralis major, Latissimus dorsi, and Teres major, and by the weight of the limb; it is *rotated outward* by the Infraspinatus and Teres minor; and it is*rotated inward* by the Subscapularis, Latissimus dorsi, Teres major, Pectoralis major, and the anterior fibers of the Deltoideus. 12

The most striking peculiarities in this joint are: (1) The large size of the head of the humerus in comparison with the depth of the glenoid cavity, even when this latter is supplemented by the glenoidal labrum. (2) The looseness of the capsule of the joint. (3) The intimate connection of the capsule with the muscles attached to the head of the humerus. (4) The peculiar relation of the tendon of the long head of the Biceps brachii to the joint. 13

It is in consequence of the relative sizes of the two articular surfaces, and the looseness of the articular capsule, that the joint enjoys such free movement in all directions. When these movements of the arm are arrested in the shoulder-joint by the contact of the bony surfaces, and by the tension of the fibers of the capsule, together with that of the muscles acting as accessory ligaments, the arm can be carried considerably farther by the movements of the scapula, involving, of course, motion at the acromio- and sternoclavicular joints. These joints are therefore to be regarded as accessory structures to the shoulder-joint (see pages 314 and 316). The extent of the scapular movements is very considerable, especially in extreme elevation of the arm, a movement best accomplished when the arm is thrown somewhat forward and outward, because the margin of the head of the humerus is by no means a true circle; its greatest diameter is from the intertubercular groove, downward, medialward, and backward, and the greatest elevation of the arm can be obtained by rolling its articular surface in the direction of this measurement. The great width of the central portion of the humeral head also allows of very free horizontal movement when the arm is raised to a right angle, in which movement the arch formed by the acromion, the coracoid process and the coracoacromial ligament, constitutes a sort of supplemental articular cavity for the head of the bone. 14

The looseness of the capsule is so great that the arm will fall about 2.5 cm. from the scapula when the muscles are dissected from the capsule, and an opening made in it to counteract the atmospheric pressure. The movements of the joint, therefore, are not regulated by the capsule so much as by the surrounding muscles and by the pressure of the atmosphere, an arrangement which "renders the movements of the joint much more easy than they would otherwise have been, and permits a swinging, pendulum-like vibration of the limb when the muscles are at rest" (Humphry). The fact, also, that in all ordinary positions of the joint the capsule is not put on the stretch, enables the arm to move freely in all directions. Extreme movements are checked by the tension of appropriate portions of the capsule, as well as by the interlooking of the bones. Thus it is said that "abduction is checked by the contact of the great tuberosity with the upper edge of the glenoid cavity; adduction by the tension of the coracohumeral ligament" (Beaunis et Bouchard). Cleland 71 maintains that the limitations of movement at the shoulder-joint are 15

due to the structure of the joint itself, the glenoidal labrum fitting, in different positions of the elevated arm, into the anatomical neck of the humerus.

The scapula is capable of being moved upward and downward, forward and backward, or, by a combination of these movements, circumducted on the wall of the chest. The muscles which *raise* the scapula are the upper fibers of the Trapezius, the Levator scapulæ, and the Rhomboidei; those which *depress* it are the lower fibers of the Trapezius, the Pectoralis minor, and, through the elavicle, the Subclavius. The scapula is drawn *backward*by the Rhomboidei and the middle and lower fibers of the Trapezius, and *forward* by the Serratus anterior and Pectoralis minor, assisted, when the arm is fixed, by the Pectoralis major. The mobility of the scapula is very considerable, and greatly assists the movements of the arm at the shoulder-joint. Thus, in raising the arm from the side, the Deltoideus and Supraspinatus can only lift it to a right angle with the trunk, the further elevation of the limb being effected by the Trapezius and Serratus anterior moving the scapula on the wall of the chest. This mobility is of special importance in ankylosis of the shoulder-joint, the movements of this bone compensating to a very great extent for the immobility of the joint. *16*

Cathcart [72] has pointed out that in abducting the arm and raising it above the head, the scapula rotates throughout the whole movement with the exception of a short space at the beginning and at the end; that the humerus moves on the scapula not only while passing from the hanging to the horizontal position, but also in travelling upward as it approaches the vertical above; that the clavicle moves not only during the second half of the movement but in the first as well, though to a less extent—*i. e.,* the scapula and clavicle are concerned in the first stage as well as in the second; and that the humerus is partly involved in the second as well as chiefly in the first. *17*

The intimate union of the tendons of the Supraspinatus, Infraspinatus, Teres minor and Subscapularis with the capsule, converts these muscles into elastic and spontaneously acting ligaments of the joint. *18*

The peculiar relations of the tendon of the long head of the Biceps branchii to the shoulder-joint appear to subserve various purposes. In the first place, by its connection with both the shoulder and elbow the muscle harmonizes the action of the two joints, and acts as an elastic ligament in all positions, in the manner previously discussed (see page 287). It strengthens the upper part of the articular cavity, and prevents the head of the humerus from being pressed up against the acromion, when the Deltoideus contracts; it thus fixes the head of the humerus as the center of motion in the glenoid cavity. By its passage along the intertubercular groove it assists in steadying the head of the humerus in the various movements of the arm. When the arm is raised from the side it assists the Supraspinatus and Infraspinatus in rotating the head of the humerus in the glenoid cavity. It also holds the head of the bone firmly in contact with the glenoid cavity, and prevents its slipping over its lower edge, or being displaced by the action of the Latissimus dorsi and Pectoralis major, as in climbing and many other movements. *19*

Note 70. The long tendon of origin of the biceps brachii also acts as one of the ligaments of this joint. See the observations on page 287, on the function of the muscles passing over more than one joint. [back]

Note 71. Journal of Anatomy and Physiology, 1867, i. 85. [back]

Note 72. Ibid., 1884, vol. xviii. [back]

6d. Elbow-joint

(Articulatio Cubiti) (Figs. 329, 330)

The elbow-joint is a ginglymus or hinge-joint. The trochlea of the humerus is received into the semilunar notch of the ulna, and the capitulum of the humerus articulates with the fovea on the head of the radius. The articular surfaces are connected together by a **capsule,** which is thickened medially and laterally, and, to a less extent, in front and behind. These thickened portions are usually described as distinct ligaments under the following names:

The Anterior.	The Posterior.
The Ulnar Collateral.	The Radial Collateral.

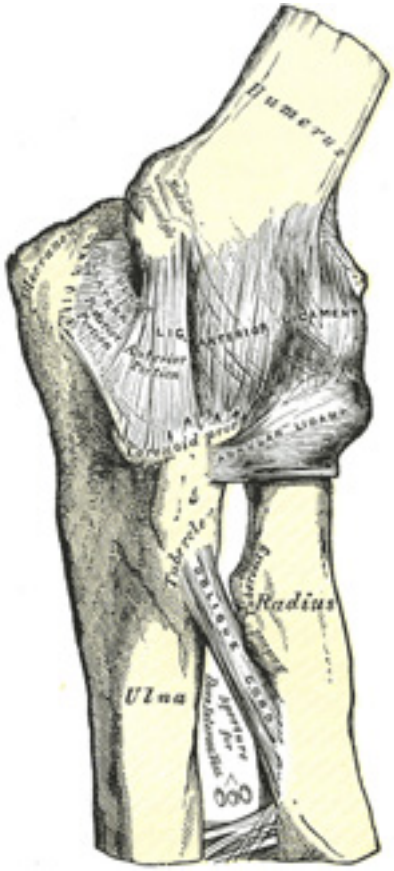

FIG. 329– Left elbow-joint, showing anterior and ulnar collateral ligaments. (See enlarged image)

FIG. 330– Left elbow-joint, showing posterior and radial collateral ligaments. (See enlarged image)

The Anterior Ligament (Fig. 329).—The anterior ligament is a broad and thin fibrous layer covering the anterior surface of the joint. It is attached to the *front* of the medial epicondyle and to the front of the humerus immediately above the coronoid and radial fossæ *below,* to the anterior surface of the coronoid process of the ulna and to the annular ligament (page 324), being continuous on either side with the collateral ligaments. Its superficial fibers pass obliquely from the medial epicondyle of the humerus to the annular ligament. The middle fibers, vertical in direction, pass from the upper part of the coronoid depression and become partly blended with the preceding, but are inserted mainly into the anterior surface of the coronoid process. The deep or transverse set intersects these at right angles. This ligament is in relation, in *front,* with the 2

Brachialis, except at its most lateral part.

The Posterior Ligament (Fig. 330).—This posterior ligament is thin and membranous, and consists of transverse and oblique fibers. *Above,* it is attached to the humerus immediately behind the capitulum and close to the medial margin of the trochlea, to the margins of the olecranon fossa, and to the back of the lateral epicondyle some little distance from the trochlea. Below, it is fixed to the upper and lateral margins of the olecranon, to the posterior part of the annular ligament, and to the ulna behind the radial notch. The transverse fibers form a strong band which bridges across the olecranon fossa; under cover of this band a pouch of synovial membrane and a pad of fat project into the upper part of the fossa when the joint is extended. In the fat are a few scattered fibrous bundles, which pass from the deep surface of the transverse band to the upper part of the fossa. This ligament is in relation, *behind,* with the tendon of the Triceps brachii and the Anconæus. 3

The Ulnar Collateral Ligament (*ligamentum collaterale ulnare; internal lateral ligament*) (Fig. 329).—This ligament is a thick triangular band consisting of two portions, an anterior and posterior united by a thinner intermediate portion. The **anterior portion,** directed obliquely forward, is attached, *above,* by its apex, to the front part of the medial epicondyle of the humerus; and, *below,* by its broad base to the medial margin of the coronoid process. The **posterior portion,** also of triangular form, is attached, *above,* by its apex, to the lower and back part of the medial epicondyle; *below,* to the medial margin of the olecranon. Between these two bands a few intermediate fibers descend from the medial epicondyle to blend with a *transverse band* which bridges across the notch between the olecranon and the coronoid process. This ligament is in relation with the Triceps brachii and Flexor carpi ulnaris and the ulnar nerve, and gives origin to part of the Flexor digitorum sublimis. 4

The Radial Collateral Ligament (*ligamentum collaterale radiale; external lateral ligament*) (Fig. 330).—This ligament is a short and narrow fibrous band, less distinct than the ulnar collateral, attached, *above,* to a depression below the lateral epicondyle of the humerus; *below,* to the annular ligament, some of its most posterior fibers passing over that ligament, to be inserted into the lateral margin of the ulna. It is intimately blended with the tendon of origin of the Supinator. 5

Synovial Membrane (Figs. 331, 332).—The synovial membrane is very extensive. It extends from the margin of the articular surface of the humerus, and lines the coronoid, radial and olecranon fossæ on that bone; it is reflected over the deep surface of the capsule and forms a pouch between the radial notch, the deep surface of the annular ligament, and the circumference of the head of the radius. Projecting between the radius and ulna into the cavity is a crescentic fold of synovial membrane, suggesting the division of the joint into two; one the humeroradial, the other the humeroulnar. 6

Between the capsule and the synovial membrane are three masses of fat: the largest, over the olecranon fossa, is pressed into the fossa by the Triceps brachii during the flexion; the second, over the coronoid fossa, and the third, over the radial fossa, are pressed by the Brachialis into their respective fossæ during extension. 7

The **muscles** in relation with the joint are, in *front,* the Brachialis; *behind,* the Triceps brachii and Anconæus; *laterally,* the Supinator, and the common tendon of origin of the Extensor muscles; *medially,* the common tendon of origin of the Flexor muscles, and the Flexor carpi ulnaris. 8

The **arteries** supplying the joint are derived from the anastomosis between the profunda and the superior and inferior ulnar collateral branches of the brachial, with the anterior, posterior, and interosseous recurrent branches of the ulnar, and the recurrent branch of the radial. These vessels 9

form a complete anastomotic network around the joint.

The **nerves** of the joint are a twig from the ulnar, as it passes between the medial condyle and the olecranon; a filament from the musculocutaneous, and two from the median. *10*

Movements.—The elbow-joint comprises three different portions—viz., the joint between the ulna and humerus, that between the head of the radius and the humerus, and the proximal radioulnar articulation, described below. All these articular surfaces are enveloped by a common synovial membrane, and the movements of the whole joint should be studied together. The combination of the movements of flexion and extension of the forearm with those of pronation and supination of the hand, which is ensured by the two being performed at the same joint, is essential to the accuracy of the various minute movements of the hand. *11*

The portion of the joint between the ulna and humerus is a simple hinge-joint, and allows of movements of flexion and extension only. Owing to the obliquity of the trochlea of the humerus, this movement does not take place in the antero-posterior plane of the body of the humerus. When the forearm is extended and supinated, the axes of the arm and forearm are not in the same line; the arm forms an obtuse angle with the forearm, the hand and forearm being directed lateral-ward. During flexion, however, the forearm and the hand tend to approach the middle line of the body, and thus enable the hand to be easily carried to the face. The accurate adaptation of the trochlea of the humerus, with its prominences and depressions, to the semilunar notch of the ulna, prevents any lateral movement. *Flexion* is produced by the action of the Biceps brachii and Brachialis, assisted by the Brachioradialis and the muscles arising from the medial condyle of the humerus; *extension,* by the Triceps brachii and Anconæus, assisted by the Extensors of the wrist, the Extensor digitorum communis, and the Extensor digiti quinti proprius. *12*

FIG. 331– Capsule of elbow-joint (distended). Anterior aspect. (See enlarged image)

FIG. 332– Capsule of elbow-joint (distended). Posterior aspect. (See enlarged image)

The joint between the head of the radius and the capitulum of the humerus is an arthrodial joint. The bony surfaces would of themselves constitute an enarthrosis and allow of movement in all directions, were it not for the annular ligament, by which the head of the radius is bound to the radial notch of the ulna, and which prevents any separation of the two bones laterally. It is to the same ligament that the head of the radius owes its security from dislocation, which would otherwise tend to occur, from the shallowness of the cup-like surface on the head of the radius. In fact, but for this ligament, the tendon of the Biceps brachii would be liable to pull the head of the radius out of the joint. The head of the radius is not in complete contact with the capitulum of the humerus in all positions of the joint. The capitulum occupies only the anterior and inferior surfaces of the lower end of the humerus, so that in complete extension a part of the radial head can be plainly felt projecting at the back of the articulation. In full flexion the movement of the radial head is hampered by the compression of the surrounding soft parts, so that the freest rotatory movement of the radius on the humerus (pronation and supination) takes place in semiflexion, in which position the two articular

surfaces are in most intimate contact. Flexion and extension of the elbow-joint are limited by the tension of the structures on the front and back of the joint; the limitation of flexion is also aided by the soft structures of the arm and forearm coming into contact.

In any position of flexion or extension, the radius, carrying the hand with it, can be rotated in the proximal radioulnar joint. The hand is directly articulated to the lower surface of the radius only, and the ulnar notch on the lower end of the radius travels around the lower end of the ulna. The latter bone is excluded from the wrist-joint by the articular disk. Thus, rotation of the head of the radius around an axis passing through the center of the radial head of the humerus imparts circular movement to the hand through a very considerable arc.

6e. Radioulnar Articulation

(Articulatio Radioulnaris) *1*

The articulation of the radius with the ulna is effected by ligaments which connect together the extremities as well as the bodies of these bones. The ligaments may, consequently, be subdivided into three sets: 1, those of the proximal radioulnar articulation; 2, the middle radioulnar ligaments; 3, those of the distal radioulnar articulation.

Proximal Radioulnar Articulation (*articulatio radioulnaris proximalis; superior radioulnar joint*).—This articulation is a trochoid or pivot- *2*
joint between the circumference of the head of the radius and the ring formed by the radial notch of the ulna and the *annular ligament*.

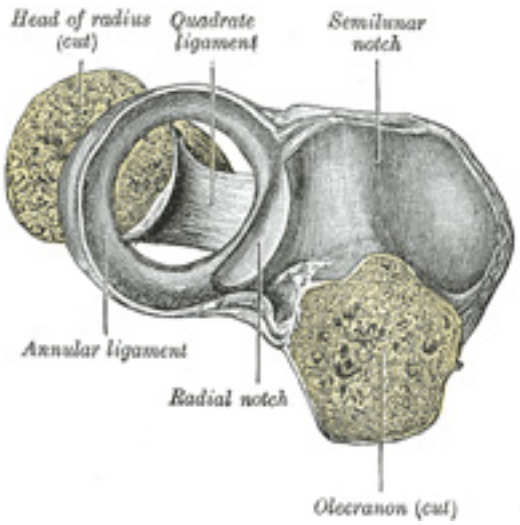

FIG. 333– Annular ligament of radius, from above. The head of the radius has been sawn off and the bone dislodged from the ligament. (See enlarged image)

The Annular Ligament (*ligamentum annulare radii; orbicular ligament*) (Fig. 333).—This ligament is a strong band of fibers, which encircles the head of the radius, and retains it in contact with the radial notch of the ulna. It forms about four-fifths of the osseo-fibrous ring, and is attached to the anterior and posterior margins of the radial notch; a few of its lower fibers are continued around below the cavity and form at this level a complete fibrous ring. Its upper border blends with the anterior and posterior ligaments of the elbow, while from its lower border a thin loose membrane passes to be attached to the neck of the radius; a thickened band which extends from the inferior border of the annular ligament below the radial notch to the neck of the radius is known as the **quadrate ligament.** The **superficial surface** of the annular ligament is strengthened by the radial collateral ligament of the elbow, and affords origin to part of the Supinator. Its *deep surface* is smooth, and lined by synovial membrane, which is continuous with that of the elbow-joint. *3*

Movements.—The movements allowed in this articulation are limited to rotatory movements of the head of the radius within the ring formed by the annular ligament and the radial notch of the ulna; rotation forward being called *pronation;* rotation backward,*supination*. Supination is performed by the Biceps brachii and Supinator, assisted to a slight extent by the Extensor muscles of the thumb. Pronation is performed by the Pronator teres and Pronator quadratus. *4*

Middle Radioulnar Union.—The shafts of the radius and ulna are connected by the Oblique Cord and the Interosseous Membrane. 5

The Oblique Cord (*chorda obliqua; oblique ligament*) (Fig. 329).—The oblique cord is a small, flattened band, extending downward and lateralward, from the lateral side of the tubercle of the ulna at the base of the coronoid process to the radius a little below the radial tuberosity. Its fibers run in the opposite direction to those of the interosseous membrane. It is sometimes wanting. 6

The Interosseous Membrane (*membrana interossea antebrachii*).—The interosseous membrane is a broad and thin plane of fibrous tissue descending obliquely downward and medialward, from the interosseous crest of the radius to that of the ulna; the lower part of the membrane is attached to the posterior of the two lines into which the interosseous crest of the radius divides. It is deficient above, commencing about 2.5 cm. beneath the tuberosity of the radius; is broader in the middle than at either end; and presents an oval aperture a little above its lower margin for the passage of the volar interosseous vessels to the back of the forearm. This membrane serves to connect the bones, and to increase the extent of surface for the attachment of the deep muscles. Between its upper border and the oblique cord is a gap, through which the dorsal interosseous vessels pass. Two or three fibrous bands are occasionally found on the dorsal surface of this membrane; they descend obliquely from the ulna toward the radius, and have consequently a direction contrary to that of the other fibers. The membrane is in relation, in *front,* by its upper three-fourths, with the Flexor pollicis longus on the radial side, and with the Flexor digitorum profundus on the ulnar, lying in the interval between which are the volar interosseous vessels and nerve; by its lower fourth with the Pronator quadratus; *behind,* with the Supinator, Abductor pollicis longus, Extensor pollicis brevis, Extensor pollicis longus, Extensor indicis proprius; and, near the wrist, with the volar interosseous artery and dorsal interosseous nerve. 7

Distal Radioulnar Articulation (*articulatio radioulnaris distalis; inferior radioulnar joint*).—This is a pivot-joint formed between the head of the ulna and the ulnar notch on the lower end of the radius. The articular surfaces are connected together by the following ligaments: 8

The Volar Radioulnar. The Dorsal Radioulnar.

The Articular Disk.

The Volar Radioulnar Ligament (*anterior radioulnar ligament*) (Fig. 334).—This ligament is a narrow band of fibers extending from the anterior margin of the ulnar notch of the radius to the front of the head of the ulna. 9

The Dorsal Radioulnar Ligament (*posterior radioulnar ligament*) (Fig. 335).—This ligament extends between corresponding surfaces on the dorsal aspect of the articulation. 10

The Articular Disk (*discus articularis; triangular fibrocartilage*) (Fig. 336).—The articular disk is triangular in shape, and is placed transversely beneath the head of the ulna, binding the lower ends of the ulna and radius firmly together. Its periphery is thicker than its center, which is occasionally perforated. It is attached by its apex to a depression between the styloid process and the head of the ulna; and by its base, which is thin, to the prominent edge of the radius, which separates the ulnar notch from the carpal articular surface. Its margins are united to the 11

ligaments of the wrist-joint. Its **upper surface,** smooth and concave, articulates with the head of the ulna, forming an arthrodial joint; its **under surface,** also concave and smooth, forms part of the wrist-joint and articulates with the triangular bone and medial part of the lunate. Both surfaces are clothed by synovial membrane; the upper, by that of the distal radioulnar articulation, the under, by that of the wrist.

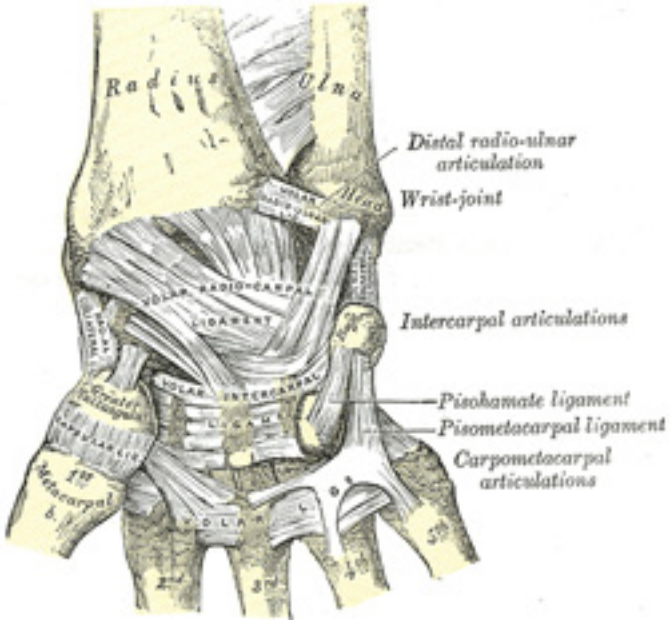

FIG. 334– Ligaments of wrist. Anterior view (See enlarged image)

Synovial Membrane (Fig. 336).—The synovial membrane of this articulation is extremely loose, and extends upward as a recess (*recessus sacciformis*) between the radius and the ulna.

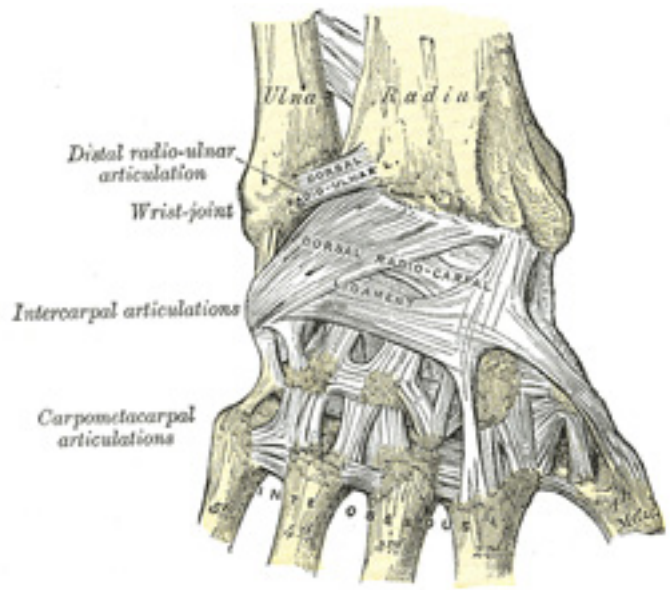

FIG. 335– Ligaments of wrist. Posterior view. (See enlarged image)

Movements.—The movements in the distal radioulnar articulation consist of rotation of the lower end of the radius around an axis which passes through the center of the head of the ulna. When the radius rotates forward, *pronation* of the forearm and hand is the result; and when backward, *supination*. It will thus be seen that in pronation and supination the radius describes the segment of a cone, the axis of which extends from the center of the head of the radius to the middle of the head of the ulna. In this movement the head of the ulna is not stationary, but describes a curve in a direction opposite to that taken by the head of the radius. This, however, is not to be regarded as a rotation of the ulna—the curve which the head of this bone describes is due to a combined antero-posterior and rotatory movement, the former taking place almost entirely at the elbow-joint, the latter at the shoulder-joint. 13

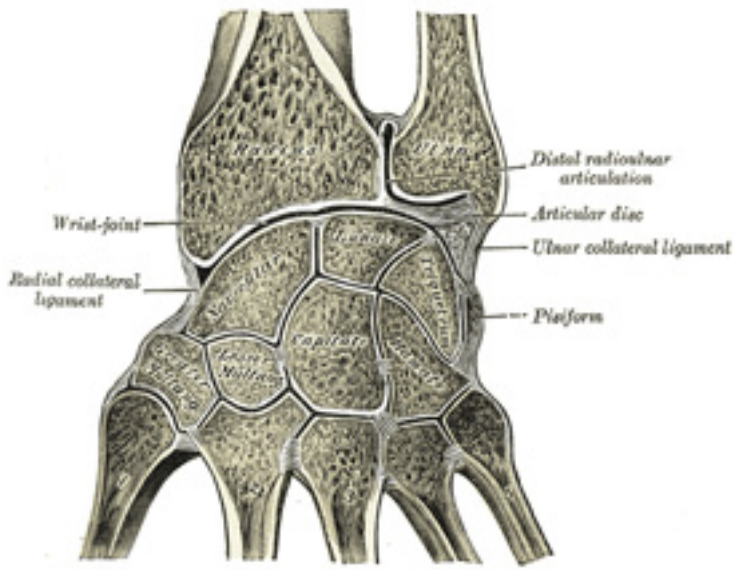

FIG. 336– Vertical section through the articulations at the wrist, showing the synovial cavities. (See enlarged image)

1F. Radiocarpal Articulation or Wrist-joint

(Articulatio Radiocarpea) (Figs. 334, 335) *1*

The wrist-joint is a condyloid articulation. The parts forming it are the lower end of the radius and under surface of the articular disk above; and the navicular, lunate, and triangular bones below. The articular surface of the radius and the under surface of the articular disk form together a transversely elliptical concave surface, the **receiving cavity.**The superior articular surfaces of the navicular, lunate, and triangular form a smooth convex surface, the **condyle,** which is received into the concavity. The joint is surrounded by a capsule, strengthened by the following ligaments:

The Volar Radiocarpal.	The Ulnar Collateral.
The Dorsal Radiocarpal.	The Radial Collateral.

The Volar Radiocarpal Ligament (***ligamentum radiocarpeum volare; anterior ligament***) **(Fig. 334).**—This ligament is a broad membranous band, attached above to the anterior margin of the lower end of the radius, to its styloid process, and to the front of the lower end of the ulna; its fibers pass downward and medialward to be inserted into the volar surfaces of the navicular, lunate, and triangular bones, some being continued to the capitate. In addition to this broad membrane, there is a rounded fasciculus, superficial to the rest, which reaches from the base of the styloid process of the ulna to the lunate and triangular bones. The ligament is perforated by apertures for the passage of vessels, and is in relation, in *front,* with the tendons of the Flexor digitorum profundus and Flexor pollicislongus; *behind,* it is closely adherent to the anterior border of the articular disk of the distal radioulnar articulation. 2

The Dorsal Radiocarpal Ligament (***ligamentum radiocarpeum dorsale; posterior ligament***) **(Fig. 335).**—The dorsal radiocarpal ligament less thick and strong than the volar, is attached, *above,* to the posterior border of the lower end of the radius; its fibers are directed obliquely downward and medialward, and are fixed, *below,* to the dorsal surfaces of the navicular, lunate, and triangular, being continuous with those of the dorsal intercarpal ligaments. It is in relation, *behind,* with the Extensor tendons of the fingers; in *front,* it is blended with the articular disk. 3

The Ulnar Collateral Ligament (***ligamentum collaterale carpi ulnare; internal lateral ligament***) **(Fig. 334).**—The ulnar collateral ligament is a rounded cord, attached above to the end of the styloid process of the ulna, and dividing below into two fasciculi, one of which is attached to the medial side of the triangular bone, the other to the pisiform and transverse carpal ligament. 4

The Radial Collateral Ligament (***ligamentum collaterale carpi radiale; external lateral ligament***) **(Fig. 335).**—The radial collateral ligament extends from the tip of the styloid process of the radius to the radial side of the navicular, some of its fibers being prolonged to the greater multangular bone and the transverse carpal ligament. It is in relation with the radial artery, which separates the ligament from the tendons of the Abductor pollicis longus and Extensor pollicis brevis. 5

Synovial Membrane (Fig. 336).—The synovial membrane lines the deep surfaces of the ligaments above described, extending from the margin of the lower end of the radius and articular disk above to the margins of the articular surfaces of the carpal bones below. It is loose and lax, and presents numerous folds, especially behind. 6

The wrist-joint is covered in front by the Flexor, and behind by the Extensor tendons. 7

The **arteries** supplying the joint are the volar and dorsal carpal branches of the radial and ulnar, the volar and dorsal metacarpals, and some ascending branches from the deep volar arch. 8

The **nerves** are derived from the ulnar and dorsal interosseous. 9

Movements.—The movements permitted in this joint are flexion, extension, abduction, adduction, and circumduction. They will be studied with those of the carpus, with which they are combined.

6g. Intercarpal Articulations

(Articulationes Intercarpeæ; Articulations of the Carpus) 1

These articulations may be subdivided into three sets:

1. The Articulations of the Proximal Row of Carpal Bones.
2. The Articulations of the Distal Row of Carpal Bones.
3. The Articulations of the Two Rows with each Other.

Articulations of the Proximal Row of Carpal Bones.—These are arthrodial joints. The navicular, lunate, and triangular are connected by dorsal, volar, and interosseous ligaments. 2

The Dorsal Ligaments (*ligamenta intercarpea dorsalia*).—The dorsal ligaments, two in number, are placed transversely behind the bones of the first row; they connect the navicular and lunate, and the lunate and triangular. 3

The Volar ligaments (*ligamenta intercarpea volaria; palmar ligaments*).—The volar ligaments, also two, connect the navicular and lunate, and the lunate and triangular; they are less strong than the dorsal, and placed very deeply behind the Flexor tendons and the volar radiocarpal ligament. 4

The Interosseous Ligaments (*ligamenta intercarpea interossea*) (Fig. 336).—The interosseous ligaments are two narrow bundles, one connecting the lunate with the navicular, the other joining it to the triangular. They are on a level with the superior surfaces of these bones, and their upper surfaces are smooth, and form part of the convex articular surface of the wrist-joint. 5

The ligaments connecting the pisiform bone are the articular capsule and the two volar ligaments. 6

The **articular capsule** is a thin membrane which connects the pisiform to the triangular; it is lined by synovial membrane. 7

The two **volar ligaments** are strong fibrous bands; one, the **pisohamate ligament,** connects the pisiform to the hamate, the other, the **pisometacarpal ligament,** joins the pisiform to the base of the fifth metacarpal bone (Fig. 334). These ligaments are, in reality, prolongations of the tendon of the Flexor carpi ulnaris. 8

Articulations of the Distal Row of Carpal Bones.—These also are arthrodial joints; the bones are connected by dorsal, volar, and interosseous ligaments. 9

The Dorsal Ligaments (*ligamenta intercarpea dorsalia*).—The dorsal ligaments, three in number, extend transversely from one bone to another on the dorsal surface, connecting the greater with the lesser multangular, the lesser multangular with the capitate, and the capitate with the 10

hamate.

The Volar Ligaments (*ligamenta intercarpea volaria; palmar ligaments*).—The volar ligaments, also three, have a similar arrangement on the volar surface. *11*

The Interosseous Ligaments (*ligamenta intercarpea interossea*).—The three interosseous ligaments are much thicker than those of the first row; one is placed between the capitate and the hamate, a second between the capitate and the lesser multangular, and a third between the greater and lesser multangulars. The first is much the strongest, and the third is sometimes wanting. *12*

Articulations of the Two Rows of Carpal Bones with Each Other.—The joint between the navicular, lunate, and triangular on the one hand, and the second row of carpal bones on the other, is named the **midcarpal joint,** and is made up of three distinct portions: in the center the head of the capitate and the superior surface of the hamate articulate with the deep cup-shaped cavity formed by the navicular and lunate, and constitute a sort of ball-and-socket joint. On the radial side the greater and lesser multangulars articulate with the navicular, and on the ulnar side the hamate articulates with the triangular, forming gliding joints. *13*

The ligaments are: volar, dorsal, ulnar and radial collateral. *14*

The Volar Ligaments (*ligamenta intercarpea volaria; anterior or palmar ligaments*).—The volar ligaments consist of short fibers, which pass, for the most part, from the volar surfaces of the bones of the first row to the front of the capitate. *15*

The Dorsal Ligaments (*ligamenta intercarpea dorsalia; posterior ligaments*).—The dorsal ligaments consist of short, irregular bundles passing between the dorsal surfaces of the bones of the first and second rows. *16*

The Collateral Ligaments (*lateral ligaments*).—The collateral ligaments are very short; one is placed on the radial, the other on the ulnar side of the carpus; the former, the stronger and more distinct, connects the navicular and greater multangular, the latter the triangular and hamate; they are continuous with the collateral ligaments of the wrist-joint. In addition to these ligaments, a slender interosseous band sometimes connects the capitate and the navicular. *17*

Synovial Membrane.—The synovial membrane of the carpus is very extensive (Fig. 336), and bounds a synovial cavity of very irregular shape. The upper portion of the cavity intervenes between the under surfaces of the navicular, lunate, and triangular bones and the upper surfaces of the bones of the second row. It sends two prolongations upward—between the navicular and lunate, and the lunate and triangular—and three prolongations downward between the four bones of the second row. The prolongation between the greater and lesser multangulars, or that between the lesser multangular and capitate, is, owing to the absence of the interosseous ligament, often continuous with the cavity of the carpometacarpal joints, sometimes of the second, third, fourth, and fifth metacarpal bones, sometimes of the second and third only. In the latter condition the joint between the hamate and the fourth and fifth metacarpal bones has a separate synovial membrane. The synovial cavities of *18*

these joints are prolonged for a short distance between the bases of the metacarpal bones. There is a separate synovial membrane between the pisiform and triangular.

Movements.—The articulation of the hand and wrist considered as a whole involves four articular surfaces: (*a*) the inferior surfaces of the radius and articular disk; (*b*) the superior surfaces of the navicular, lunate, and triangular, the pisiform having no essential part in the movement of the hand; (*c*) the S-shaped surface formed by the inferior surfaces of the navicular, lunate, and triangular; (*d*) the reciprocal surface formed by the upper surfaces of the bones of the second row. These four surfaces form two joints: (1) a proximal, the wrist-joint proper; and (2) a distal, the mid-carpal joint. *19*

1. The wrist-joint proper is a true condyloid articulation, and therefore all movements but rotation are permitted. Flexion and extension are the most free, and of these a greater amount of extension than of flexion is permitted, since the articulating surfaces extend farther on the dorsal than on the volar surfaces of the carpal bones. In this movement the carpal bones rotate on a transverse axis drawn between the tips of the styloid processes of the radius and ulna. A certain amount of adduction (or ulnar flexion) and abduction (or radial flexion) is also permitted. The former is considerably greater in extent than the latter on account of the shortness of the styloid process of the ulna, abduction being soon limited by the contact of the styloid process of the radius with the greater multangular. In this movement the carpus revolves upon an antero-posterior axis drawn through the center of the wrist. 73 Finally, circumduction is permitted by the combined and consecutive movements of adduction, extension, abduction, and flexion. No rotation is possible, but the effect of rotation is obtained by the pronation and supination of the radius on the ulna. The movement of *flexion* is performed by the Flexor carpi radialis, the Flexor carpi ulnaris, and the Palmaris longus; *extension* by the Extensores carpi radiales longus and brevis and the Extensor carpi ulnaris; *adduction* (ulnar flexion) by the Flexor carpi ulnaris and the Extensor carpi ulnaris; and *abduction* (radial flexion) by the Abductor pollicis longus, the Extensors of the thumb, and the Extensores carpi radiales longus and brevis and the Flexor carpi radialis. When the fingers are extended, flexion of the wrist is performed by the Flexor carpi radialis and ulnaris and extension is aided by the Extensor digitorum communis. When the fingers are flexed, flexion of the wrist is aided by the Flexores digitorum sublimis and profundus, and extension is performed by the Extensores carpi radiales and ulnaris. *20*

2. The chief movements permitted in the mid-carpal joint are flexion and extension and a slight amount of rotation. In flexion and extension, which are the movements most freely enjoyed, the greater and lesser multangulars on the radial side and the hamate on the ulnar side glide forward and backward on the navicular and triangular respectively, while the head of the capitate and the superior surface of the hamate rotate in the cup-shaped cavity of the navicular and lunate. Flexion at this joint is freer than extension. A very trifling amount of rotation is also permitted, the head of the capitate rotating around a vertical axis drawn through its own center, while at the same time a slight gliding movement takes place in the lateral and medial portions of the joint. *21*

Note 73. H. M. Johnston (Journal of Anatomy and Physiology, vol. xli) maintains that n ulnar and radial flexion only slight lateral movement occurs at the radiocarpal joint, and that in complete flexion and extension of the hand there is a small degree of ulnar flexion at the radiocarpal joint. [back]

6h. Carpometacarpal Articulations

(Articulationes Carpometacarpeæ)

Carpometacarpal Articulation of the Thumb (*articulatio carpometacarpea pollicis*).—This is a joint of reciprocal reception between the first metacarpal and the greater multangular; it enjoys great freedom of movement on account of the configuration of its articular surfaces, which are saddle-shaped. The joint is surrounded by a capsule, which is thick but loose, and passes from the circumference of the base of the metacarpal bone to the rough edge bounding the articular surface of the greater multangular; it is thickest laterally and dorsally, and is lined by synovial membrane. *1*

Movements.—In this articulation the movements permitted are flexion and extension in the plane of the palm of the hand, abduction and adduction in a plane at right angles to the palm, circumduction, and opposition. It is by the movement of opposition that the tip of the thumb is brought into contact with the volar surfaces of the slightly flexed fingers. This movement is effected through the medium of a small sloping facet on the anterior lip of the saddle-shaped articular surface of the greater multangular. The Flexor muscles pull the corresponding part of the articular surface of the metacarpal bone on to this facet, and the movement of opposition is then carried out by the Adductors. *2*

Flexion of this joint is produced by the Flexores pollicis longus and brevis, assisted by the Opponens pollicis and the Adductor pollicis. Extension is effected mainly by the abductor pollicis longus, assisted by the Extensores pollicis longus and brevis. Adduction is carried out by the Adductor; abduction mainly by the Abductores pollicis longus and brevis, assisted by the Extensors. *3*

Articulations of the Other Four Metacarpal Bones with the Carpus (*articulationes carpometacarpeæ*).—The joints between the carpus and the second, third, fourth, and fifth metacarpal bones are arthrodial. The bones are united by dorsal, volar, and interosseous ligaments. *4*

The Dorsal Ligaments (*ligamenta carpometacarpea dorsalia*).—The dorsalligaments, the strongest and most distinct, connect the carpal and metacarpal bones on their dorsal surfaces. The second metacarpal bone receives two fasciculi, one from the greater, the other from the lesser multangular; the third metacarpal receives two, one each from the lesser multangular and capitate; the fourth two, one each from the capitate and hamate; the fifth receives a single fasciculus from the hamate, and this is continuous with a similar ligament on the volar surface, forming an incomplete capsule. *5*

The Volar Ligaments (*ligamenta carpometacarpea volaria; palmar ligaments*).—The volar ligaments have a somewhat similar arrangement, with the exception of those of the third metacarpal, which are three in number: a lateral one from the greater multangular, situated superficial to the sheath of the tendon of the Flexor carpi radialis; and intermediate one from the capitate; and a medial one from the hamate. *6*

The Interosseous Ligaments.—The interosseous ligaments consist of short, thick fibers, and are limited to one part of the carpometacarpal articulation; they connect the contiguous inferior angles of the capitate and hamate with the adjacent surfaces of the third and fourth metacarpal *7*

bones.

Synovial Membrane.—The synovial membrane is a continuation of that of the intercarpal joints. Occasionally, the joint between the hamate and the fourth and fifth metacarpal bones has a separate synovial membrane. 8

The synovial membranes of the wrist and carpus (Fig. 336) are thus seen to be five in number. The *first* passes from the lower end of the ulnar to the ulnar notch of the radius, and lines the upper surface of the articular disk. The *second* passes from the articular disk and the lower end of the radius above, to the bones of the first row below. The *third,* the most extensive, passes between the contiguous margins of the two rows of carpal bones, and sometimes, in the event of one of the interosseous ligaments being absent, between the bones of the second row to the carpal extremities of the second, third, fourth, and fifth metacarpal bones. The *fourth* extends from the margin of the greater multangular to the metacarpal bone of the thumb. The *fifth* runs between the adjacent margins of the triangular and pisiform bones. Occasionally the fourth and fifth carpometacarpal joints have a separate synovial membrane. 9

Movements.—The movements permitted in the carpometacarpal articulations of the fingers are limited to slight gliding of the articular surfaces upon each other, the extent of which varies in the different joints. The metacarpal bone of the little finger is most movable, then that of the ring finger; the metacarpal bones of the index and middle fingers are almost immovable.

6i. Intermetacarpal Articulations

(Articulationes Intermetacarpeæ; Articulations of the Metacarpal Bones with Each Other) 1

The bases of the second, third, fourth and fifth metacarpal bones articulate with one another by small surfaces covered with cartilage, and are connected together by dorsal, volar, and interosseous ligaments.

The **dorsal** (*ligamenta basium oss. metacarp. dorsalia*) and **volar ligaments** (*ligamenta basium oss. metacarp. volaria; palmar ligaments*) pass transversely from one bone to another on the dorsal and volar surfaces. The **interosseous ligaments** (*ligamenta basium oss. metacarp. interossea*) connect their contiguous surfaces, just distal to their collateral articular facets. 2

The **synovial membrane** for these joints is continuous with that of the carpometacarpal articulations. 3

The Transverse Metacarpal Ligament (*ligamentum capitulorum* [*oss. metacarpalium*]*transversum*) (Fig. 337).—This ligament is a narrow fibrous band, which runs across the volar surfaces of the heads of the second, third, fourth and fifth metacarpal bones, connecting them together. It is blended with the volar (glenoid) ligaments of the metacarpophalangeal articulations. Its volar surface is concave where the Flexor tendons pass over it; behind it the tendons of the Interossei pass to their insertions.

6j. Metacarpophalangeal Articulations

(Articulationes Metacarpophalangeæ; Metacarpophalangeal Joints) (Figs. 337, 338) *1*

These articulations are of the condyloid kind, formed by the reception of the rounded heads of the metacarpal bones into shallow cavities on the proximal ends of the first phalanges, with the exception of that of the thumb, which presents more of the characters of a ginglymoid joint. Each joint has a volar and two collateral ligaments.

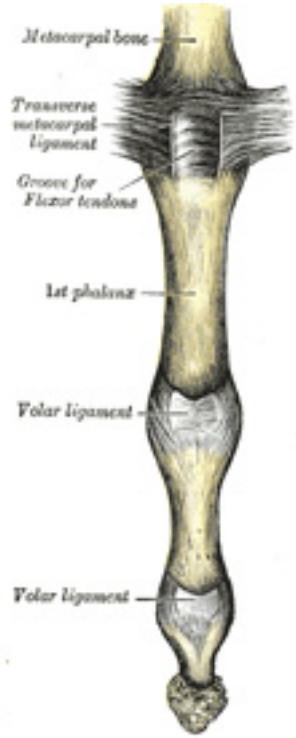

FIG. 337– Metacarpophalangeal articulation and articulations of digit. Volar aspect. (See enlarged image)

FIG. 338– Metacarpophalangeal articulation and articulations of digit. Ulnar aspect. (See enlarged image)

The Volar Ligaments (*glenoid ligaments of Cruveilhier; palmar or vaginal ligaments*).—The volar ligaments are thick, dense, fibrocartilaginous structures, placed upon the volar surfaces of the joints in the intervals between the collateral ligaments, to which they are connected; they are loosely united to the metacarpal bones, but are very firmly attached to the bases of the first phalanges. Their volar surfaces are intimately blended with the transverse metacarpal ligament, and present grooves for the passage of the Flexor tendons, the sheaths surrounding which are connected to the sides of the grooves. Their deep surfaces form parts of the articular facets for the heads of the metacarpal bones, and are lined by synovial membranes. 2

The Collateral Ligaments (*ligamenta collateralia; lateral ligaments*).—The collateral ligaments are strong, rounded cords, placed on the sides of the joints; each is attached by one extremity to the posterior tubercle and adjacent depression on the side of the head of the metacarpal bone, and by the other to the contiguous extremity of the phalanx. 3

The dorsal surfaces of these joints are covered by the expansions of the Extensor tendons, together with some loose areolar tissue which connects the deep surfaces of the tendons to the bones. 4

Movements.—The movements which occur in these joints are flexion, extension, adduction, abduction, and circumduction; the movements of abduction and adduction are very limited, and cannot be performed when the fingers are flexed.

6k. Articulations of the Digits

(Articulationes Digitorum Manus; Interphalangeal Joints) (Figs. 337, 338) 1

The interphalangeal articulations are hinge-joints; each has a volar and two collateral ligaments. The arrangement of these ligaments is similar to those in the metacarpophalangeal articulations. The Extensor tendons supply the place of posterior ligaments.

Movements.—The only movements permitted in the interphalangeal joints are flexion and extension; these movements are more extensive between the first and second phalanges than between the second and third. The amount of flexion is very considerable, but extension is limited by the volar and collateral ligaments. 2

Muscles Acting on the Joints of the Digits.—Flexion of the metacarpophalangeal joints of the fingers is effected by the Flexores digitorum sublimis and profundus, Lumbricales, and Interossei, assisted in the case of the little finger by the Flexor digiti quinti brevis. Extension is produced by the Extensor digitorum communis, Extensor indicis proprius, and Extensor digiti quinti proprius. 3

Flexion of the interphalangeal joints of the fingers is accomplished by the Flexor digitorum profundus acting on the proximal and distal joints and by the Flexor digitorum sublimis acting on the proximal joints. Extension is effected mainly by the Lumbricales and Interossei, the long Extensors having little or no action upon these joints. 4

Flexion of the metacarpophalangeal joint of the thumb is effected by the Flexores pollicis longus and brevis; extension by the Extensores pollicis longus and brevis. Flexion of the interphalangeal joint is accomplished by the Flexor pollicis longus, and extension by the Extensor pollicis longus. 5

7. Articulations of the Lower Extremity. a. Coxal Articulation or Hip-joint

The articulations of the Lower Extremity comprise the following:

I. Hip.	V. Intertarsal.
II. Knee.	VI. Tarsometatarsal.
III. Tibiofibular.	VII. Intermetatarsal.
IV. Ankle.	VIII. Metatarsophalangeal.

IX. Articulations of the Digits.

1

2

Coxal Articulation or Hip-joint (Articulatio Coxæ)

This articulation is an enarthrodial or ball-and-socket joint, formed by the reception of the head of the femur into the cup-shaped cavity of the acetabulum. The articular cartilage on the head of the femur, thicker at the center than at the circumference, covers the entire surface with the exception of the fovea capitis femoris, to which the ligamentum teres is attached; that on the acetabulum forms an incomplete marginal ring, the lunate surface. Within the lunate surface there is a circular depression devoid of cartilage, occupied in the fresh state by a mass of fat, covered by synovial membrane. The ligaments of the joint are:

The Articular Capsule.	The Pubocapsular.
The Iliofemoral.	The Ligamentum Teres Femoris.
The Ischiocapsular.	The Glenoidal Labrum.

The Transverse Acetabular

The Articular Capsule (*capsula articularis; capsular ligament*) (Figs. 339, 340).—The articular capsule is strong and dense. *Above,* it is attached to the margin of the acetabulum 5 to 6 mm. beyond the glenoidal labrum behind; but in *front,* it is attached to the outer margin of the labrum, and, opposite to the notch where the margin of the cavity is deficient, it is connected to the transverse ligament, and by a few fibers to the edge of the obturator foramen. It surrounds the neck of the femur, and is attached, in *front,* to the intertrochanteric line; *above,* to the base of the neck; *behind,* to the neck, about 1.25 cm. above the intertrochanteric crest; *below,* to the lower part of the neck, close to the lesser trochanter. From its femoral attachment some of the fibers are reflected upward along the neck as longitudinal bands, termed **retinacula.** The capsule is much thicker at the upper and forepart of the joint, where the greatest amount of resistance is required; behind and below, it is thin and loose. It consists of two sets of fibers, circular and longitudinal. The circular fibers, **zona orbicularis,** are most abundant at the lower and back part of the capsule (Fig. 342), and form a sling or collar around the neck of the femur. Anteriorly they blend with the deep surface of the iliofemoral ligament, and gain an attachment to the anterior inferior iliac spine. The longitudinal fibers are greatest in amount at the upper and front part of the capsule, where they are reinforced by distinct bands, or accessory ligaments, of which the most important is the **iliofemoral ligament.** The *3*

other accessory bands are known as the **pubocapsular** and the **ischiocapsular ligaments.** The external surface of the capsule is rough, covered by numerous muscles, and separated in front from the Psoas major and Iliacus by a bursa, which not infrequently communicates by a circular aperture with the cavity of the joint.

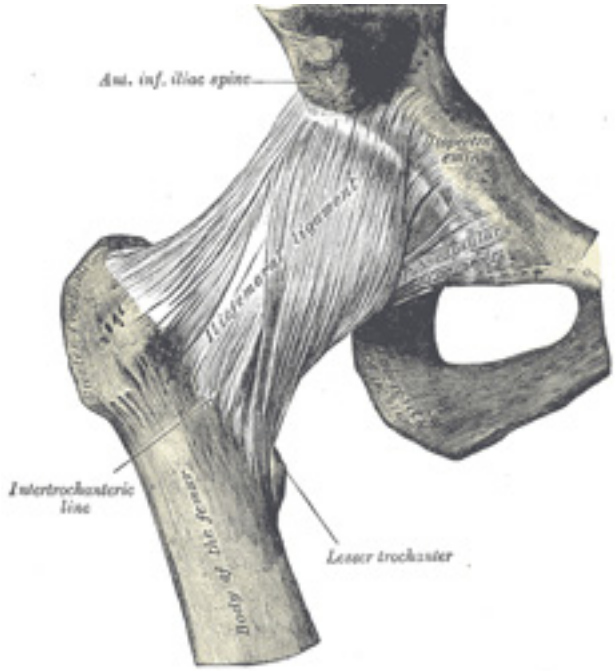

FIG. 339– Right hip-joint from the front. (Spalteholz.) (See enlarged image)

The Iliofemoral Ligament (***ligamentum iliofemorale; Y-ligament; ligament of Bigelow***)**(Fig. 339).**—The iliofemoral ligament is a band of great strength which lies in front of the joint; it is intimately connected with the capsule, and serves to strengthen it in this situation. It is attached, *above,* to the lower part of the anterior inferior iliac spine; *below,* it divides into two bands, one of which passes downward and is fixed to the lower part of the intertrochanteric line; the other is directed downward and lateralward and is attached to the upper part of the same line. Between the two bands is a thinner part of the capsule. In some cases there is no division, and the ligament spreads out into a flat triangular band which is attached to the whole length of the intertrochanteric line. This ligament is frequently called the Y-shaped ligament of Bigelow; and its 4

upper band is sometimes named the**iliotrochanteric ligament.**

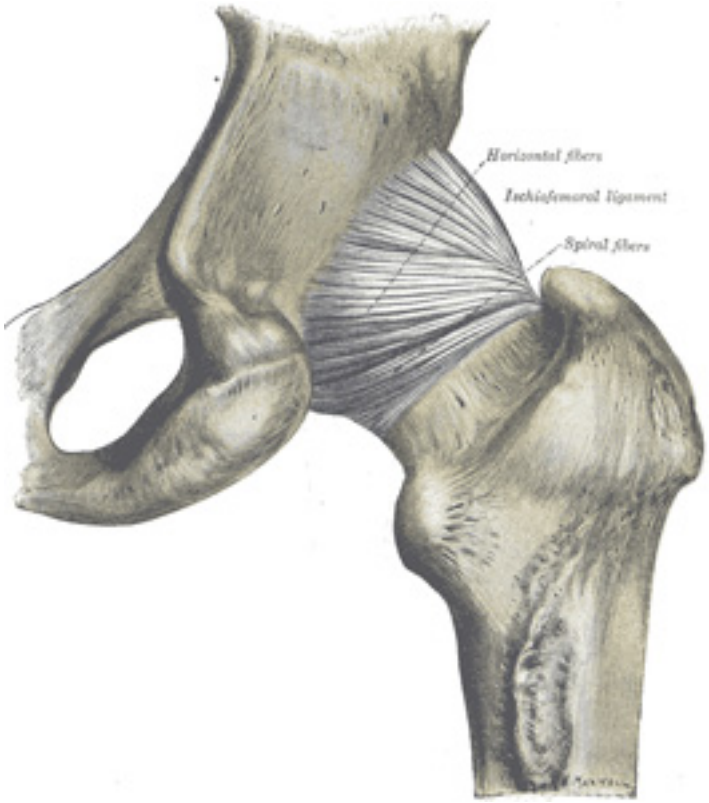

FIG. 340– The hip-joint from behind. (Quain.) (See enlarged image)

The Pubocapsular Ligament (*ligamentum pubocapsulare; pubofemoral ligament*).—This ligament is attached, *above,* to the obturator crest and the superior ramus of the pubis;*below,* it blends with the capsule and with the deep surface of the vertical band of the oliofemoral ligament. 5

The Ischiocapsular Ligament (*ligamentum ischiocapsulare; ischiocapsular band; ligament of Bertin*).—The ischiocapsular ligament consists 6

of a triangular band of strong fibers, which spring from the ischium below and behind the acetabulum, and blend with the circular fibers of the capsule (Fig. 340).

The Ligamentum Teres Femoris (Fig. 341).—The ligamentum teres femoris is a triangular, somewhat flattened band implanted by its apex into the antero-superior part of the fovea capitis femoris; its base is attached by two bands, one into either side of the acetabular notch, and between these bony attachments it blends with the transverse ligament. It is ensheathed by the synovial membrane, and varies greatly in strength in different subjects; occasionally only the synovial fold exists, and in rare cases even this is absent. The ligament is made tense when the thigh is semiflexed and the limb then adducted or rotated outward; it is, on the other hand, relaxed when the limb is abducted. It has, however, but little influence as a ligament. 7

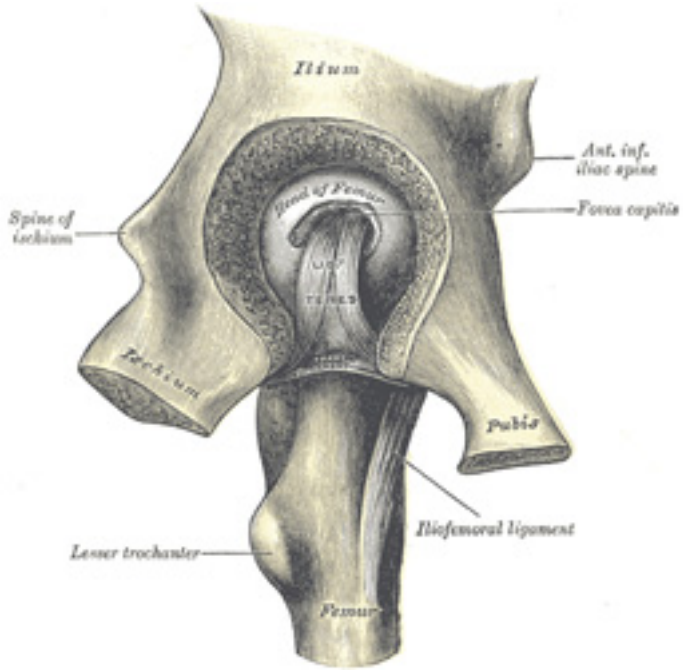

FIG. 341– Left hip-joint, opened by removing the floor of the acetabulum from within the pelvis. (See enlarged image)

The Glenoidal Labrum (*labrum glenoidale; cotyloid ligament*).—The glenoidal labrum is a fibrocartilaginous rim attached to the margin of the acetabulum, the cavity of which it deepens; at the same time it protects the edge of the bone, and fills up the inequalities of its surface. It bridges over the notch as the **transverse ligament,** and thus forms a complete circle, which closely surrounds the head of the femur and assists in holding it in its place. It is triangular on section, its base being attached to the margin of the acetabulum, while its opposite edge is free and sharp. Its two surfaces are invested by synovial membrane, the external one being in contact with the capsule, the internal one being inclined inward so as to narrow the acetabulum, and embrace the cartilaginous surface of the head of the femur. It is much thicker above and behind than below and in front, and consists of compact fibers. 8

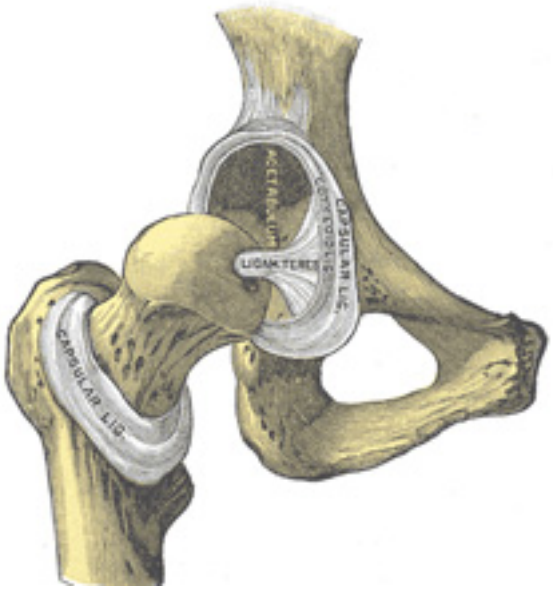

FIG. 342– Hip-joint, front view. The capsular ligament has been largely removed. (See enlarged image)

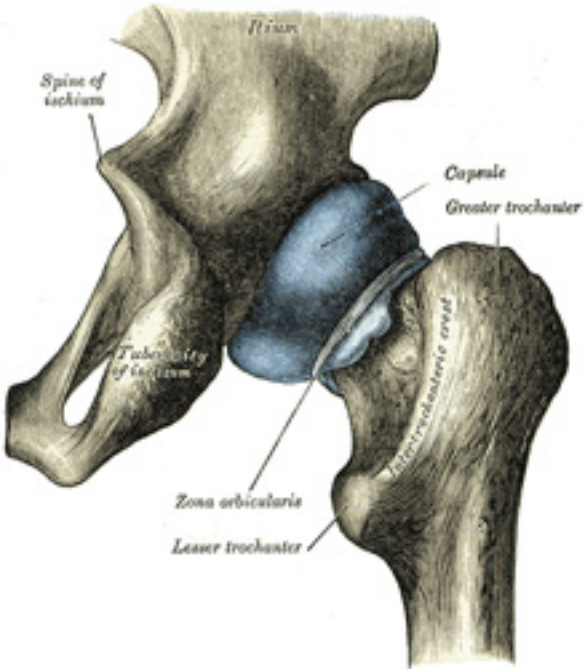

FIG. 343– Capsule of hip-joint (distended). Posterior aspect. (See enlarged image)

The Transverse Acetabular Ligament (*ligamentum transversum acetabuli; transverse ligament*).—This ligament is in reality a portion of the glenoidal labrum, though differing from it in having no cartilage cells among its fibers. It consists of strong, flattened fibers, which cross the acetabular notch, and convert it into a foramen through which the nutrient vessels enter the joint. 9

Synovial Membrane (Fig. 343).—The synovial membrane is very extensive. Commencing at the margin of the cartilaginous surface of the head of the femur, it covers the portion of the neck which is contained within the joint; from the neck it is reflected on the internal surface of the capsule, covers both surfaces of the glenoidal labrum and the mass of fat contained in the depression at the bottom of the acetabulum, and ensheathes the ligamentum teres as far as the head of the femur. The joint cavity sometimes communicates through a hole in the capsule between the vertical band of the iliofemoral ligament and the pubocapsular ligament with a bursa situated on the deep surfaces of the Psoas major and Iliacus. 10

The **muscles** in relation with the joint are, in *front,* the Psoas major and Iliacus, separated from the capsule by a bursa; *above,* the reflected head of the Rectus femoris and Glutæus minimus, the latter being closely adherent to the capsule; *medially,* the Obturator externus and Pectineus; *behind,* the Piriformis, Gemellus superior, Obturator internus, Gemellus inferior, Obturator externus, and Quadratus femoris (Fig. 344). 11

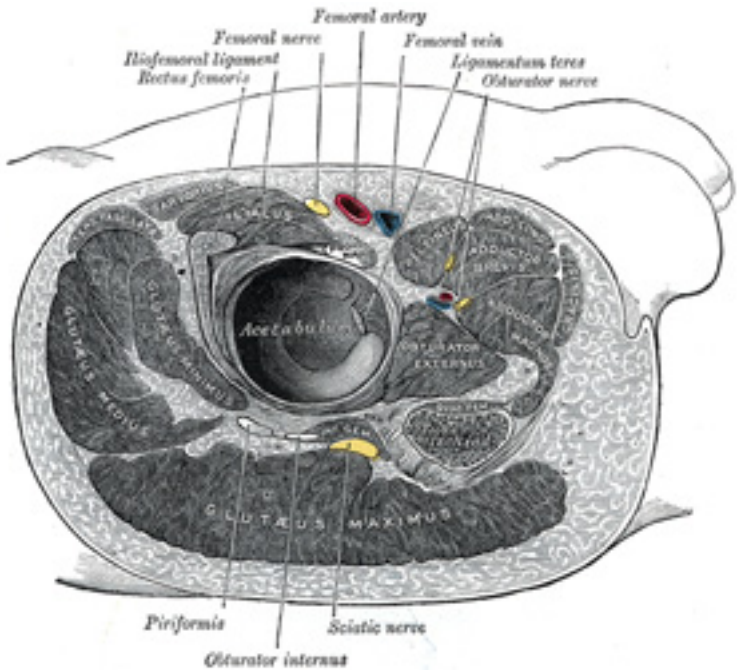

FIG. 344– Structures surrounding right hip-joint. (See enlarged image)

The **arteries** supplying the joint are derived from the obturator, medial femoral circumflex, and superior and inferior gluteals. 12

The **nerves** are articular branches from the sacral plexus, sciatic, obturator, accessory obturator, and a filament from the branch of the femoral supplying the Rectus femoris. 13

Movements.—The movements of the hip are very extensive, and consist of flexion, extension, adduction, abduction, circumduction, and rotation. 14

The length of the neck of the femur and its inclinations to the body of the bone have the effect of converting the angular movements of flexion, extension, adduction, and abduction partially into rotatory movements in the joint. Thus when the thigh is flexed or extended, the head of the femur, on account of the *medial* inclination of the neck, rotates within the acetabulum with only a slight amount of gliding to and fro. *15*
The *forward* slope of the neck similarly affects the movements of adduction and abduction. Conversely rotation of the thigh which is permitted by the *upward* inclination of the neck, is not a simple rotation of the head of the femur in the acetabulum, but is accompanied by a certain amount of gliding.

The hip-joint presents a very striking contrast to the shoulder-joint in the much more complete mechanical arrangements for its security and for the limitation of its movements. In the shoulder, as has been seen, the head of the humerus is not adapted at all in size to the glenoid cavity, and is hardly restrained in any of its ordinary movements by the capsule. In the hip-joint, on the contrary, the head of the femur is closely fitted to the acetabulum for an area extending over nearly half a sphere, and at the margin of the bony cup it is still more closely embraced by the glenoidal labrum, so that the head of the femur is held in its place by that ligament even when the fibers of the capsule have been quite divided. The iliofemoral ligament is the strongest of all the ligaments in the body, and is put on the stretch by any attempt to extend the femur beyond a straight line with the trunk. That is to say, this ligament is the chief agent in maintaining the erect position without muscular fatigue; for a vertical line passing through the center of gravity of the trunk falls behind the centers of rotation in the hip-joints, and therefore the pelvis tends to fall backward, but is prevented by the tension of the iliofemoral ligaments. The security of the joint may be provided for also by the two bones being directly united through the ligamentum teres; but it is doubtful whether this ligament has much influence upon the mechanism of the joint. *16*
When the knee is flexed, flexion of the hip-joint is arrested by the soft parts of the thigh and abdomen being brought into contact, and when the knee is extended, by the action of the hamstring muscles; extension is checked by the tension of the iliofemoral ligament; adduction by the thighs coming into contact; adduction with flexion by the lateral band of the iliofemoral ligament and the lateral part of the capsule; abduction by the medial band of the iliofemoral ligament and the pubocapsular ligament; rotation outward by the lateral band of the iliofemoral ligament; and rotation inward by the ischiocapsular ligament and the hinder part of the capsule. The muscles which *flex* the femur on the pelvis are the Psoas major, Iliacus, Rectus femoris, Sartorius, Pectineus, Adductores longus and brevis, and the anterior fibers of the Glutæi medius and minimus. *Extension* is mainly performed by the Glutæus maximus, assisted by the hamstring muscles and the ischial head of the Adductor magnus. The thigh is *adducted* by the Adductores magnus, longus, and brevis, the Pectineus, the Gracilis, and lower part of the Glutæus maximus, and *abducted* by the Glutæi medius and minimus, and the upper part of the Glutæus maximus. The muscles which *rotate* the thigh *inward* are the Glutæus minimus and the anterior fibers of the Glutæus medius, the Tensor fasciæ latæ and the Iliacus and Psoas major; while those which rotate it *outward* are the posterior fibers of the Glutæus medius, the Piriformis, Obturatores externus and internus, Gemelli superior and inferior, Quadratus femoris, Glutæus maximus, the Adductores longus, brevis, and magnus, the Pectineus, and the Sartorius.

7b. The Knee-joint

(Articulatio Genu) *1*

The knee-joint was formerly described as a ginglymus or hinge-joint, but is really of a much more complicated character. It must be regarded as

consisting of three articulations in one: two condyloid joints, one between each condyle of the femur and the corresponding meniscus and condyle of the tibia; and a third between the patella and the femur, partly arthrodial, but not completely so, since the articular surfaces are not mutually adapted to each other, so that the movement is not a simple gliding one. This view of the construction of the knee-joint receives confirmation from the study of the articulation in some of the lower mammals, where, corresponding to these three subdivisions, three synovial cavities are sometimes found, either entirely distinct or only connected together by small communications. This view is further rendered probable by the existence in the middle of the joint of the two cruciate ligaments, which must be regarded as the collateral ligaments of the medial and lateral joints. The existence of the patellar fold of synovial membrane would further indicate a tendency to separation of the synovial cavity into two minor sacs, one corresponding to the lateral and the other to the medial joint.

The bones are connected together by the following ligaments: *2*

The Articular Capsule.	The Anterior Cruciate.
The Ligamentum Patellæ.	The Posterior Cruciate.
The Oblique Popliteal.	The Medial and Lateral Menisci.
The Tibial Collateral.	The Transverse.
The Fibular Collateral.	The Coronary.

The Articular Capsule (*capsula articularis; capsular ligament*) (Fig. 345).—The articular capsule consists of a thin, but strong, fibrous membrane which is strengthened in almost its entire extent by bands inseparably connected with it. Above and in front, beneath the tendon of the Quadriceps femoris, it is represented only by the synovial membrane. Its chief strengthening bands are derived from the fascia lata and from the tendons surrounding the joint. In front, expansions from the Vasti and from the fascia lata and its iliotibial band fill in the intervals between the anterior and collateral ligaments, constituting the **medial**and **lateral patellar retinacula.** Behind the capsule consists of vertical fibers which arise from the condyles and from the sides of the intercondyloid fossa of the femur; the posterior part of the capsule is therefore situated on the sides of and in front of the cruciate ligaments, which are thus excluded from the joint cavity. Behind the cruciate ligaments is the oblique popliteal ligament which is augmented by fibers derived from the tendon of the Semimembranosus. Laterally, a prolongation from the iliotibial band fills in the interval between the oblique popliteal and the fibular collateral ligaments, and partly covers the latter. Medially, expansions from the Sartorius and Semimembranosus pass upward to the tibial collateral ligament and strengthen the capsule. *3*

The Ligamentum Patellæ (*anterior ligament*) (Fig. 345).—The ligamentum patellæ is the central portion of the common tendon of the Quadriceps femoris, which is continued from the patella to the tuberosity of the tibia. It is a strong, flat, ligamentous band, about 8 cm. in length, attached, *above,* to the apex and adjoining margins of the patella and the rough depression on its posterior surface; *below,* to the tuberosity of the tibia; its superficial fibers are continuous over the front of the patella with those of the tendon of the Quadriceps femoris. The medial and lateral portions of the tendon of the Quadriceps pass down on either side of the patella, to be inserted into the upper extremity of the tibia on either side of the tuberosity; these portions merge into the capsule, as stated above, forming the medial and lateral patellar retinacula. The posterior surface of the ligamentum patellæ is separated from the synovial membrane of the joint by a large infrapatellar pad of fat, and from the tibia by a bursa. *4*

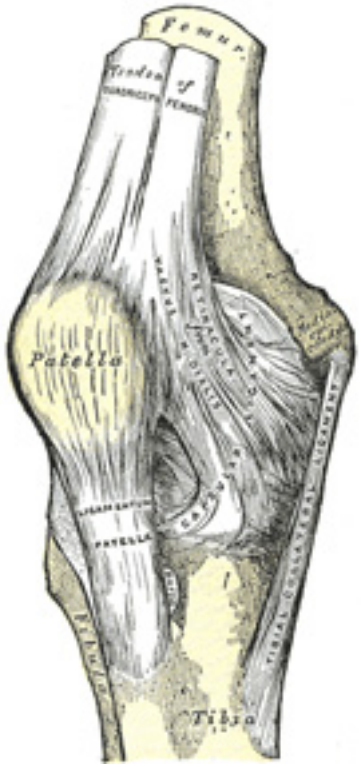

FIG. 345– Right knee-joint. Anterior view. (See enlarged image)

The Oblique Popliteal Ligament (***ligamentum popliteum obliquum; posterior ligament***)**(Fig. 346).**—This ligament is a broad, flat, fibrous band, formed of fasciculi separated from one another by apertures for the passage of vessels and nerves. It is attached above to the upper margin of the intercondyloid fossa and posterior surface of the femur close to the articular margins of the condyles, and below to the posterior margin of the head of the tibia. Superficial to the main part of the ligament is a strong fasciculus, derived from the tendon of the Semimembranosus and passing from the back part of the medial condyle of the tibia obliquely upward and lateralward to the back part of the lateral condyle of the femur. The oblique popliteal ligament forms part of the floor of the popliteal fossa, and the popliteal artery rests upon it. 5

The Tibial Collateral Ligament (***ligamentum collaterale tibiale; internal lateral ligament***) **(Fig. 345).**—The tibial collateral is a broad, flat, membranous band, situated nearer to the back than to the front of the joint. It is attached, *above,* to the medial condyle of the femur immediately below the adductor tubercle; *below,* to the medial condyle and medial surface of the body of the tibia. The fibers of the posterior part of the ligament are short and incline backward as they descend; they are inserted into the tibia above the groove for the Semimembranosus. The anterior part of the ligament is a flattened band, about 10 cm. long, which inclines forward as it descends. It is inserted into the medial surface of the body of the tibia about 2.5 cm. below the level of the condyle. It is crossed, at its lower part, by the tendons of the Sartorius, Gracilis, and Semitendinosus, a bursa being interposed. Its deep surface covers the inferior medial genicular vessels and nerve and the anterior portion of the tendon of the Semimembranosus, with which it is connected by a few fibers; it is intimately adherent to the medial meniscus.

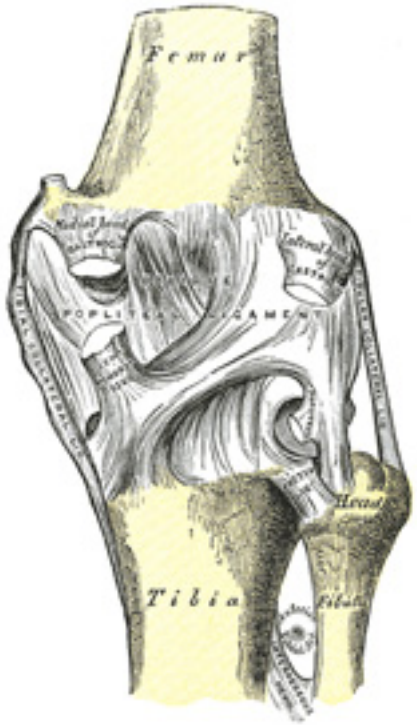

FIG. 346– Right knee-joint. Posterior view. (See enlarged image)

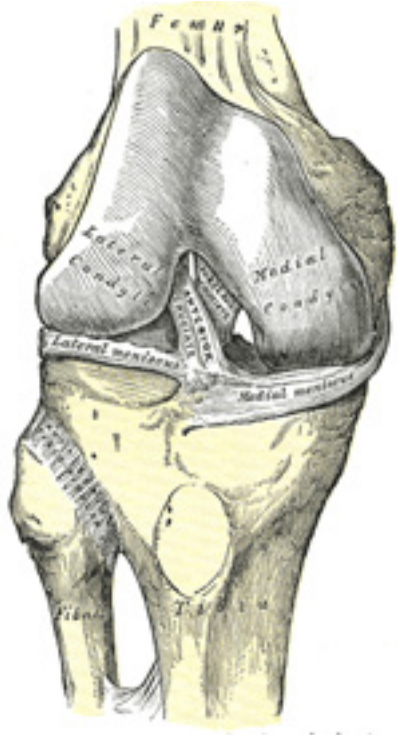

FIG. 347– Right knee-joint, from the front, showing interior ligaments. (See enlarged image)

The Fibular Collateral Ligament (***ligamentum collaterale fibulare; external lateral or long external lateral ligament***) **(Fig. 348).**—The fibular collateral is a strong, rounded, fibrous cord, attached, *above,* to the back part of the lateral condyle of the femur, immediately above the groove for the tendon of the Popliteus; *below,* to the lateral side of the head of the fibula, in front of the styloid process. The greater part of its lateral surface is covered by the tendon of the Biceps femoris; the tendon, however, divides at its insertion into two parts, which are separated by the ligament. Deep to the ligament are the tendon of the Popliteus, and the inferior lateral genicular vessels and nerve. The ligament has no attachment to the lateral meniscus. 7

An inconstant bundle of fibers, the **short fibular collateral ligament,** is placed behind and parallel with the preceding, attached, *above,* to the 8

lower and back part of the lateral condyle of the femur; *below,* to the summit of the styloid process of the fibula. Passing deep to it are the tendon of the Popliteus, and the inferior lateral genicular vessels and nerve.

The Cruciate Ligaments (*ligamenta cruciata genu; crucial ligaments*).—The cruciate ligaments are of considerable strength, situated in the middle of the joint, nearer to its posterior than to its anterior surface. They are called *cruciate* because they cross each other somewhat like the lines of the letter X; and have received the names **anterior** and**posterior,** from the position of their attachments to the tibia. 9

The Anterior Cruciate Ligament (*ligamentum cruciatum anterius; external crucial ligament*) (Fig. 347) is attached to the depression in front of the intercondyloid eminence of the tibia, being blended with the anterior extremity of the lateral meniscus; it passes upward, backward, and lateralward, and is fixed into the medial and back part of the lateral condyle of the femur. 10

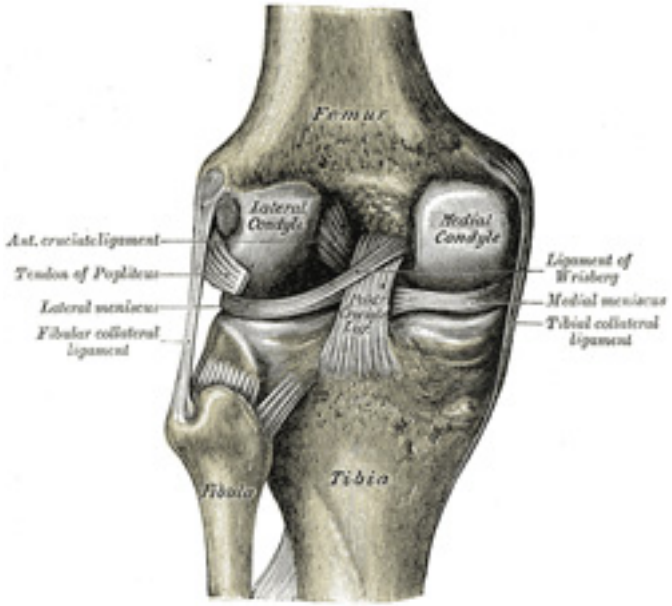

FIG. 348– Left knee-joint from behind, showing interior ligaments. (See enlarged image)

The Posterior Cruciate Ligament (*ligamentum cruciatum posterius; internal crucial ligament*) (Fig. 348) is stronger, but shorter and less oblique in its direction, than the anterior. It is attached to the posterior intercondyloid fossa of the tibia, and to the posterior extremity of the lateral meniscus; and passes upward, forward, and medialward, to be fixed into the lateral and front part of the medial condyle of the femur. 11

The Menisci (*semilunar fibrocartilages*) (Fig. 349).—The menisci are two crescentic lamellæ, which serve to deepen the surfaces of the head of the tibia for articulation with the condyles of the femur. The peripheral border of each meniscus is thick, convex, and attached to the inside of the capsule of the joint; the opposite border is thin, concave, and free. The upper surfaces of the menisci are concave, and in contact with the condyles of the femur; their lower surfaces are flat, and rest upon the head of the tibia; both surfaces are smooth, and invested by synovial membrane. Each meniscus covers approximately the peripheral two-thirds of the corresponding articular surface of the tibia. 12

The **medial meniscus** (*meniscus medialis; internal semilunar fibrocartilage*) is nearly semicircular in form, a little elongated from before backward, and broader behind than in front; its anterior end, thin and pointed, is attached to the anterior intercondyloid fossa of the tibia, in front of the anterior cruciate ligament; its posterior end is fixed to the posterior intercondyloid fossa of the tibia, between the attachments of the lateral meniscus and the posterior cruciate ligament. 13

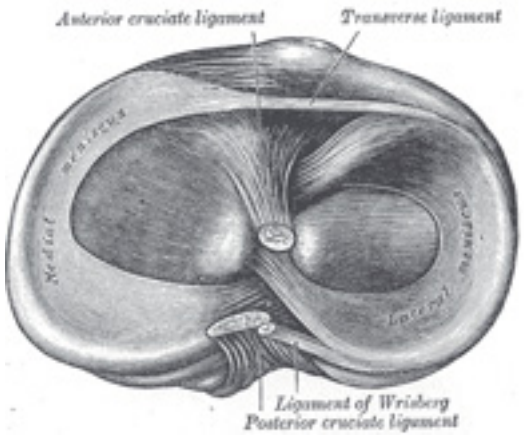

FIG. 349– Head of right tibia seen from above, showing menisci and attachments of ligaments. (See enlarged image)

The **lateral meniscus** (*meniscus lateralis; external semilunar fibrocartilage*) is nearly circular and covers a larger portion of the articular surface than the medial one. It is grooved laterally for the tendon of the Popliteus, which separates it from the fibular collateral ligament. Its anterior end is attached in front of the intercondyloid eminence of the tibia, lateral to, and behind, the anterior cruciate ligament, with which it blends; the posterior end is attached behind the intercondyloid eminence of the tibia and in front of the posterior end of the medial meniscus. The anterior attachment of the lateral meniscus is twisted on itself so that its free margin looks backward and upward, its anterior end resting on a sloping shelf of bone on the front of the lateral process of the intercondyloid eminence. Close to its posterior attachment it sends off a strong fasciculus, the **ligament of Wrisberg**(Figs. 348, 349), which passes upward and medialward, to be inserted into the medial condyle of the femur, 14

immediately behind the attachment of the posterior cruciate ligament. Occasionally a small fasciculus passes forward to be inserted into the lateral part of the anterior cruciate ligament. The lateral meniscus gives off from its anterior convex margin a fasciculus which forms the transverse ligament.

The Transverse Ligament (*ligamentum transversum genu*).—The transverse ligament connects the anterior convex margin of the lateral meniscus to the anterior end of the medial meniscus; its thickness varies considerably in different subjects, and it is sometimes absent. *15*

The **coronary ligaments** are merely portions of the capsule, which connect the periphery of each meniscus with the margin of the head of the tibia. *16*

Synovial Membrane.—The synovial membrane of the knee-joint is the largest and most extensive in the body. Commencing at the upper border of the patella, it forms a large cul-de-sac beneath the Quadriceps femoris (Figs. 350, 351) on the lower part of the front of the femur, and frequently communicates with a bursa interposed between the tendon and the front of the femur. The pouch of synovial membrane between the Quadriceps and front of the femur is supported, during the movements of the knee, by a small muscle, the Articularis genu, which is inserted into it. On either side of the patella, the synovial membrane extends beneath the aponeuroses of the Vasti, and more especially beneath that of the Vastus medialis. Below the patella it is separated from the ligamentum patellæ by a considerable quantity of fat, known as the **infrapatellar pad.** From the medial and lateral borders of the articular surface of the patella, reduplications of the synovial membrane project into the interior of the joint. These form two fringe-like folds termed the **alar folds;**below, these folds converge and are continued as a single band, the **patellar fold**(*ligamentum mucosum*), to the front of the intercondyloid fossa of the femur. On either side of the joint, the synovial membrane passes downward from the femur, lining the capsule to its point of attachment to the menisci; it may then be traced over the upper surfaces of these to their free borders, and thence along their under surfaces to the tibia (Figs. 351, 352). At the back part of the lateral meniscus it forms a cul-de-sac between the groove on its surface and the tendon of the Popliteus; it is reflected across the front of the cruciate ligaments, which are therefore situated outside the synovial cavity. *17*

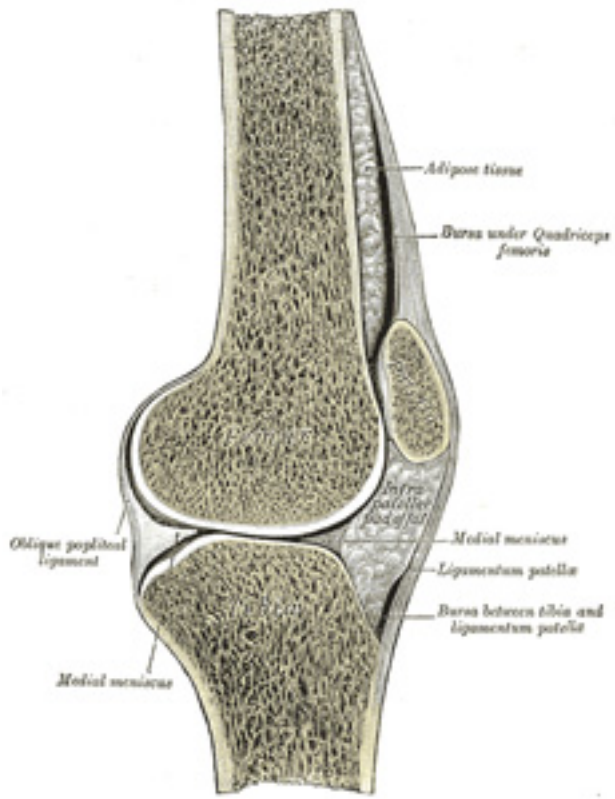

FIG. 350– Sagittal section of right knee-joint. (See enlarged image)

Bursæ.—The bursæ near the knee-joint are the following: In front there are *four* bursæ: a large one is interposed between the patella and the skin, a small one between the upper part of the tibia and the ligamentum patellæ, a third between the lower part of the tuberosity of the tibia and the skin, and a fourth between the anterior surface of the lower part of the femur and the deep surface of the Quadriceps femoris, usually communicating with the knee-joint. Laterally there are four bursæ: (1) one (which sometimes communicates with the joint) between the lateral head of the Gastrocnemius and the capsule; (2) one between the fibular collateral ligament and the tendon of the Biceps; (3) one between the fibular collateral ligament and the tendon of the Popliteus (this is sometimes only an expansion from the next bursa); (4) one between the tendon

of the Popliteus and the lateral condyle of the femur, usually an extension from the synovial membrane of the joint. Medially, there are five bursæ: (1) one between the medial head of the Gastrocnemius and the capsule; this sends a prolongation between the tendon of the medial head of the Gastrocnemius and the tendon of the Semimembranosus and often communicates with the joint; (2) one superficial to the tibial collateral ligament, between it and the tendons of the Sartorius, Gracilis, and Semitendinosus; (3) one deep to the tibial collateral ligament, between it and the tendon of the Semimembranosus (this is sometimes only an expansion from the next bursa); (4) one between the tendon of the Semimembranosus and the head of the tibia; (5) occasionally there is a bursa between the tendons of the Semimembranosus and Semitendinosus.

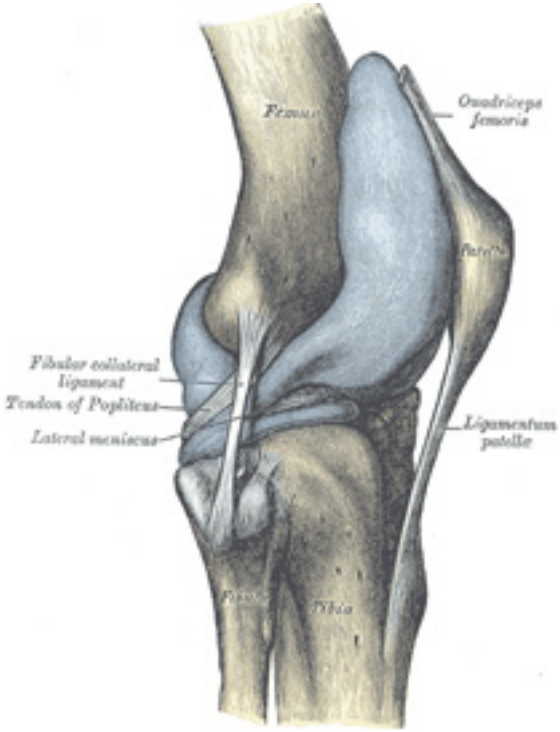

FIG. 351– Capsule of right knee-joint (distended). Lateral aspect. (See enlarged image)

Structures Around the Joint.—In front, and at the sides, is the Quadriceps femoris; laterally the tendons of the Biceps femoris and Popliteus

and the common peroneal nerve; medially, the Sartorius, Gracilis, Semitendinosus, and Semimembranosus; behind, the popliteal vessels and the tibial nerve, Popliteus, Plantaris, and medial and lateral heads of the Gastrocnemius, some lymph glands, and fat.

The **arteries** supplying the joint are the highest genicular (anastomotica magna), a branchof the femoral, the genicular branches of the popliteal, the recurrent branches of the anterior tibial, and the descending branch from the lateral femoral circumflex of the profunda femoris. 20

The **nerves** are derived from the obturator, femoral, tibial, and common peroneal. 21

Movements.—The movements which take place at the knee-joint are flexion and extension, and, in certain positions of the joint, internal and external rotation. The movements of flexion and extension at this joint differ from those in a typical hinge-joint, such as the elbow, in that (*a*) the axis around which motion takes place is not a fixed one, but shifts forward during extension and backward during flexion; (*b*) the commencement of flexion and the end of extension are accompanied by rotatory movements associated with the fixation of the limb in a position of great stability. The movement from full flexion to full extension may therefore be described in three phases: 22

1. In the fully flexed condition the posterior parts of the femoral condyles rest on the corresponding portions of the meniscotibial surfaces, and in this position a slight amount of simple rolling movement is allowed. 23

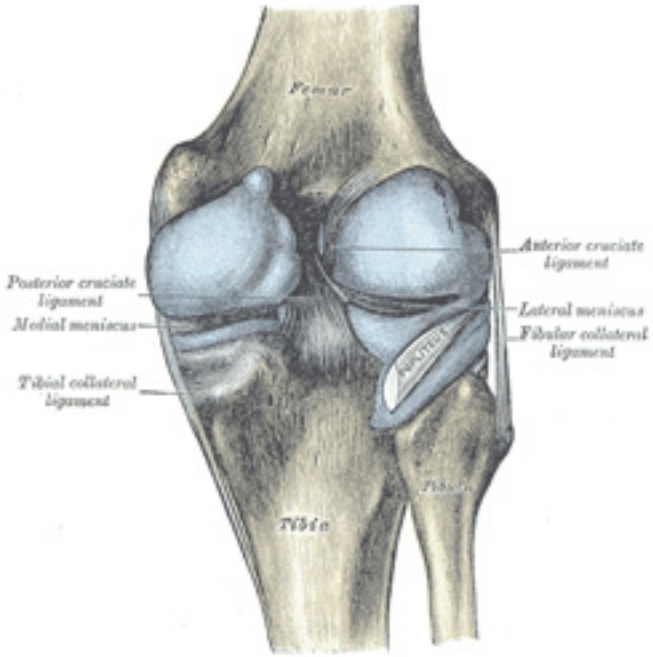

FIG. 352– Capsule of right knee-joint (distended). Posterior aspect. (See enlarged image)

2. During the passage of the limb from the flexed to the extended position a gliding movement is superposed on the rolling, so that the axis, which at the commencement is represented by a line through the inner and outer condyles of the femur, gradually shifts forward. In this part of the movement, the posterior two-thirds of the tibial articular surfaces of the two femoral condyles are involved, and as these have similar curvatures and are parallel to one another, they move forward equally. 24

3. The lateral condyle of the femur is brought almost to rest by the tightening of the anterior cruciate ligament; it moves, however, slightly forward and medialward, pushing before it the anterior part of the lateral meniscus. The tibial surface on the medial condyle is prolonged farther forward than that on the lateral, and this prolongation is directed lateralward. When, therefore, the movement forward of the condyles is checked by the anterior cruciate ligament, continued muscular action causes the medial condyle, dragging with it the meniscus, to travel backward and medialward, thus producing an internal rotation of the thigh on the leg. When the position of full extension is reached the lateral part of the groove on the lateral condyle is pressed against the anterior part of the corresponding meniscus, while the medial part of the groove rests on the articular margin in front of the lateral process of the tibial intercondyloid eminence. Into the groove on the medial condyle is fitted the anterior part of the medial meniscus, while the anterior cruciate ligament and the articular margin in front of the medial process of the tibial intercondyloid eminence are received into the forepart of the intercondyloid fossa of the femur. This third phase by which all these parts are brought into accurate apposition is known as the "screwing home," or locking movement of the joint. 25

The complete movement of flexion is the converse of that described above, and is therefore preceded by an external rotation of the femur which unlocks the extended joint. 26

The axes around which the movements of flexion and extension take place are not precisely at right angles to either bone; in flexion, the femur and tibia are in the same plane, but in extension the one bone forms an angle, opening lateralward with the other. 27

In addition to the rotatory movements associated with the completion of extension and the initiation of flexion, rotation inward or outward can be effected when the joint is partially flexed; these movements take place mainly between the tibia and the menisci, and are freest when the leg is bent at right angles with the thigh. 28

Movements of Patella.—The articular surface of the patella is indistinctly divided into seven facets—upper, middle, and lower horizontal pairs, and a medial perpendicular facet(Fig. 353). When the knee is forcibly flexed, the medial perpendicular facet is in contact with the semilunar surface on the lateral part of the medial condyle; this semilunar surface is a prolongation backward of the medial part of the patellar surface. As the leg is carried from the flexed to the extended position, first the highest pair, then the middle pair, and lastly the lowest pair of horizontal facets is successively brought into contact with the patellar surface of the femur. In the extended position, when the Quadriceps femoris is relaxed, the patella lies loosely on the front of the lower end of the femur. 29

During flexion, the ligamentum patellæ is put upon the stretch, and in extreme flexion the posterior cruciate ligament, the oblique popliteal, and collateral ligaments, and, to a slight extent, the anterior cruciate ligament, are relaxed. Flexion is checked during life by the contact of the leg with the thigh. When the knee-joint is fully extended the oblique popliteal and collateral ligaments, the anterior cruciate ligament, and the posterior cruciate ligament, are rendered tense; in the act of extending the knee, the ligamentum patellæ is tightened by the Quadriceps femoris, but in full extension with the heel supported it is relaxed. Rotation inward is checked by the anterior cruciate ligament; rotation outward tends to 30

uncross and relax the cruciate ligaments, but is checked by the tibial collateral ligament. The main function of the cruciate ligament is to act as a direct bond between the tibia and femur and to prevent the former bone from being carried too far backward or forward. They also assist the collateral ligaments in resisting any bending of the joint to either side. The menisci are intended, as it seems, to adapt the surfaces of the tibia to the shape of the femoral condyles to a certain extent, so as to fill up the intervals which would otherwise be left in the varying positions of the joint, and to obviate the jars which would be so frequently transmitted up the limb in jumping or by falls on the feet; also to permit of the two varieties of motion, flexion and extension, and rotation, as explained above. The patella is a great defence to the front of the knee-joint, and distributes upon a large and tolerably even surface, during kneeling, the pressure which would otherwise fall upon the prominent ridges of the condyles; it also affords leverage to the Quadriceps femoris.

FIG. 353– Posterior surface of the right patella, showing diagrammatically the areas of contact with the femur in different positions of the knee. (See enlarged image)

When standing erect in the attitude of "attention," the weight of the body falls in front of a line carried across the centers of the knee-joints, and therefore tends to produce overextension of the articulations; this, however, is prevented by the tension of the anterior cruciate, oblique popliteal, and collateral ligaments. 31

Extension of the leg on the thigh is performed by the Quadriceps femoris; *flexion* by the Biceps femoris, Semitendinosus, and Semimembranosus, assisted by the Gracilis, Sartorius, Gastrocnemius, Popliteus, and Plantaris. *Rotation outward* is effected by the Biceps femoris, and *rotation inward* by the Popliteus, Semitendinosus, and, to a slight extent, the Semimembranosus, the Sartorius, and the Gracilis. The Popliteus comes into action especially at the commencement of the movement of flexion of the knee; by its contraction the leg is rotated inward, or, if the tibia be fixed, the thigh is rotated outward, and the knee-joint is unlocked.

7c. Articulations between the Tibia and Fibula

The articulations between the tibia and fibula are effected by ligaments which connect the extremities and bodies of the bones. The ligaments 1

may consequently be subdivided into three sets: (1) those of the Tibiofibular articulation; (2) the interosseous membrane; (3) those of the Tibiofibular syndesmosis.

Tibiofibular Articulation (*articulatio tibiofibularis; superior tibiofibular articulation*).—This articulation is an arthrodial joint between the lateral condyle of the tibia and the head of the fibula. The contiguous surfaces of the bones present flat, oval facets covered with cartilage and connected together by an articular capsule and by anterior and posterior ligaments. 2

The Articular Capsule (*capsula articularis; capsular ligament*).—The articular capsule surrounds the articulation, being attached around the margins of the articular facets on the tibia and fibula; it is much thicker in front than behind. 3

The Anterior Ligament (*anterior superior ligament*).—The anterior ligament of the head of the fibula (Fig. 347) consists of two or three broad and flat bands, which pass obliquely upward from the front of the head of the fibula to the front of the lateral condyle of the tibia. 4

The Posterior Ligament (*posterior superior ligament*).—The posterior ligament of the head of the fibula (Fig. 348) is a single thick and broad band, which passes obliquely upward from the back of the head of the fibula to the back of the lateral condyle of the tibia. It is covered by the tendon of the Popliteus. 5

Synovial Membrane.—A synovial membrane lines the capsule; it is continuous with that of the knee-joint in occasional cases when the two joints communicate. 6

Interosseous Membrane (*membrana interossea cruris; middle tibiofibular ligament*).—An interosseous membrane extends between the interosseous crests of the tibia and fibula, and separates the muscles on the front from those on the back of the leg. It consists of a thin, aponeurotic lamina composed of oblique fibers, which for the most part run downward and lateralward; some few fibers, however, pass in the opposite direction. It is broader above than below. Its upper margin does not quite reach the tibiofibular joint, but presents a free concave border, above which is a large, oval aperture for the passage of the anterior tibial vessels to the front of the leg. In its lower part is an opening for the passage of the anterior peroneal vessels. It is continuous below with the interosseous ligament of the tibiofibular syndesmosis, and presents numerous perforations for the passage of small vessels. It is in relation, in *front,* with the Tibialis anterior, Extensor digitorum longus, Extensor hallucis proprius, Peronæus tertius, and the anterior tibial vessels and deep peroneal nerve; *behind,* with the Tibialis posterior and Flexor hallucis longus. 7

Tibiofibular Syndesmosis (*syndesmosis tibiofibularis; inferior tibiofibular articulation*).—This syndesmosis is formed by the rough, convex surface of the medial side of the lower end of the fibula, and a rough concave surface on the lateral side of the tibia. Below, to the extent of about 4 mm. these surfaces are smooth, and covered with cartilage, which is continuous with that of the ankle-joint. The ligaments are: anterior, posterior, inferior transverse, and interosseous. 8

The Anterior Ligament (*ligamentum malleoli lateralis anterius; anterior inferior ligament*).—The anterior ligament of the lateral malleolus (Fig. 355) is a flat, triangular band of fibers, broader below than above, which extends obliquely downward and lateralward between the adjacent margins of the tibia and fibula, on the front aspect of the syndesmosis. It is in relation, in *front,* with the Peronæus tertius, the aponeurosis of the leg, and the integument; *behind,* with the interosseous ligament; and lies in contact with the cartilage covering the talus. *9*

The Posterior Ligament (*ligamentum malleoli lateralis posterius; posterior inferior ligament*).—The posterior ligament of the lateral malleolus (Fig. 355), smaller than the preceding, is disposed in a similar manner on the posterior surface of the syndesmosis. *10*

The Inferior Transverse Ligament.—The inferior transverse ligament lies in front of the posterior ligament, and is a strong, thick band, of yellowish fibers which passes transversely across the back of the joint, from the lateral malleolus to the posterior border of the articular surface of the tibia, almost as far as its malleolar process. This ligament projects below the margin of the bones, and forms part of the articulating surface for the talus. *11*

The Interosseous Ligament.—The interosseous ligament consists of numerous short, strong, fibrous bands, which pass between the contiguous rough surfaces of the tibia and fibula, and constitute the chief bond of union between the bones. It is continuous, above, with the interosseous membrane (Fig. 356). *12*

Synovial Membrane.—The synovial membrane associated with the small arthrodial part of this joint is continuous with that of the ankle-joint. *13*

7d. Talocrural Articulation or Ankle-joint

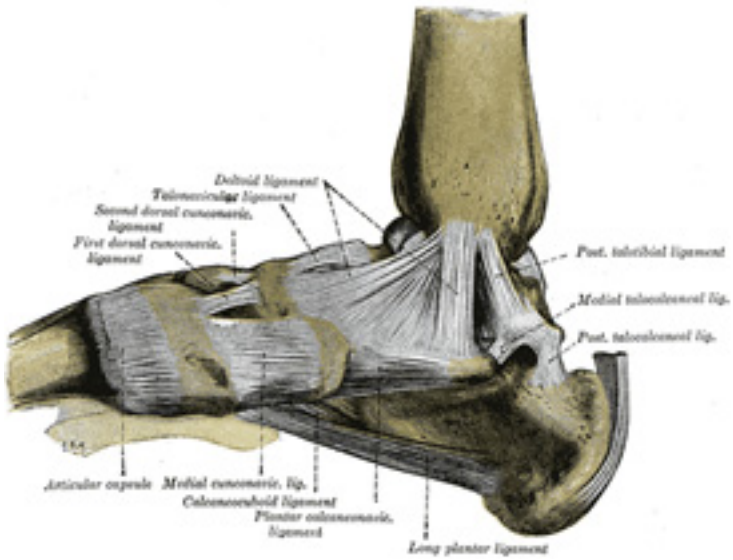

FIG. 354– Ligaments of the medial aspect of the foot. (Quain.) (See enlarged image)

(Articulatio Talocruralis; Tibiotarsal Articulation) *1*

The ankle-joint is a ginglymus, or hinge-joint. The structures entering into its formation are the lower end of the tibia and its malleolus, the malleolus of the fibula, and the transverse ligament, which together form a mortise for the reception of the upper convex surface of the talus and its medial and lateral facets. The bones are connected by the following ligaments:

The Articular Capsule. The Anterior Talofibular.
The Deltoid. The Posterior Talofibular.
The Calcaneofibular.

The Articular Capsule (*capsula articularis; capsular ligament*).—The articular capsule surrounds the joints, and is attached, *above,* to the borders of the articular surfaces of the tibia and malleoli; and *below,* to the talus around its upper articular surface. The anterior part of the capsule (*anterior ligament*) is a broad, thin, membranous layer, attached, *above,*to the anterior margin of the lower end of the tibia; *below,* to the *2*

talus, in front of its superior articular surface. It is in relation, in *front,* with the Extensor tendons of the toes, the tendons of the Tibialis anterior and Peronæus tertius, and the anterior tibial vessels and deep peroneal nerve. The posterior part of the capsule (*posterior ligament*) is very thin, and consists principally of transverse fibers. It is attached, *above,* to the margin of the articular surface of the tibia, blending with the transverse ligament; *below,* to the talus behind its superior articular facet. Laterally, it is somewhat thickened, and is attached to the hollow on the medial surface of the lateral malleolus.

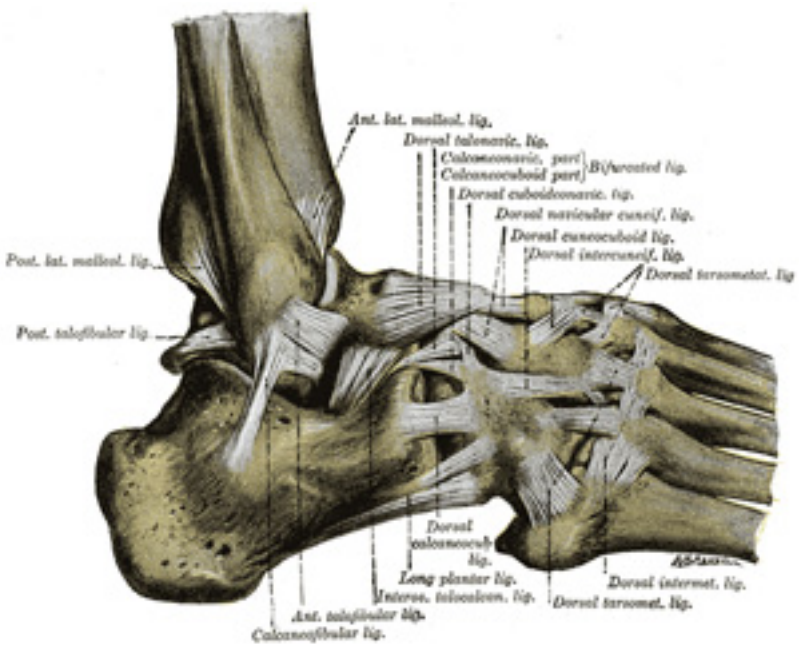

FIG. 355– The ligaments of the foot from the lateral aspect. (Quain.) (See enlarged image)

The Deltoid Ligament (*ligamentum deltoideum; internal lateral ligament*) (Fig. 331).—The deltoid ligament is a strong, flat, triangular band, attached, *above,* to the apex and anterior and posterior borders of the medial malleolus. It consists of two sets of fibers, superficial and deep. Of the superficial fibers the most anterior (*tibionavicular*) pass forward to be inserted into the tuberosity of the navicular bone, and immediately behind this they blend with the medial margin of the plantar calcaneonavicular ligament; the middle (*calcaneotibial*) descend almost perpendicularly to be inserted into the whole length of the sustentaculum tali of the calcaneus; the posterior fibers (*posterior talotibial*) pass 3

backward and lateralward to be attached to the inner side of the talus, and to the prominenttubercle on its posterior surface, medial to the groove for the tendon of the Flexor hallucis longus. The deep fibers (*anterior talotibial*) are attached, *above,* to the tip of the medial malleolus, and, *below,* to the medial surface of the talus. The deltoid ligament is covered by the tendons of the Tibialis posterior and Flexor digitorum longus.

The anterior and posterior talofibular and the calcaneofibular ligaments were formerly described as the three fasciculi of the *external lateral ligament* of the ankle-joint. 4

The Anterior Talofibular Ligament. (*ligamentum talofibulare anterius*) (Fig. 355).—The anterior talofibular ligament, the shortest of the three, passes from the anterior margin of the fibular malleolus, forward and medially, to the talus, in front of its lateral articular facet. 5

The Posterior Talofibular Ligament (*ligamentum talofibulare posterius*) (Fig. 355).—The posterior talofibular ligament, the strongest and most deeply seated, runs almost horizontally from the depression at the medial and back part of the fibular malleolus to a prominent tubercle on the posterior surface of the talus immediately lateral to the groove for the tendon of the Flexor hallucis longus. 6

The Calcaneofibular Ligament (*ligamentum calcaneofibulare*) (Fig. 355).—The calcaneofibular ligament, the longest of the three, is a narrow, rounded cord, running from the apex of the fibular malleolus downward and slightly backward to a tubercle on the lateral surface of the calcaneus. It is covered by the tendons of the Peronæi longus and brevis. 7

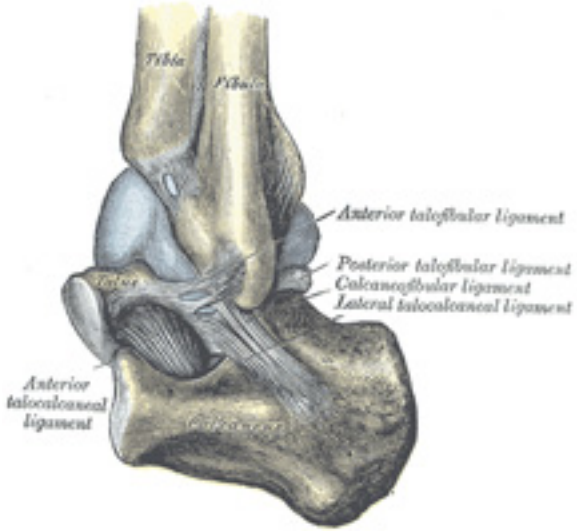

FIG. 356– Capsule of left talocrura articulation (distended). Lateral aspect. (See enlarged image)

Synovial Membrane (Fig. 356).—The synovial membrane invests the deep surfaces of the ligaments, and sends a small process upward between the lower ends of the tibia and fibula. 8

Relations.—The tendons, vessels, and nerves in connection with the joint are, in *front,* from the medial side, the Tibialis anterior, Extensor hallucis proprius, anterior tibial vessels, deep peroneal nerve, Extensor digitorum longus, and Peronæus tertius; *behind,* from the medial side, the Tibialis posterior, Flexor digitorum longus, posterior tibial vessels, tibial nerve, Flexor hallucis longus; and, in the groove behind the fibular malleolus, the tendons of the Peronæi longus and brevis. 9

The **arteries** supplying the joint are derived from the malleolar branches of the anterior tibial and the peroneal. 10

The **nerves** are derived from the deep peroneal and tibial. 11

Movements.—When the body is in the erect position, the foot is at right angles to the leg. The movements of the joint are those of dorsiflexion and extension; dorsiflexion consists in the approximation of the dorsum of the foot to the front of the leg, while in extension the heel is drawn up and the toes pointed downward. The range of movement varies in different individuals from about 50° to 90°. The transverse axis about which movement takes place is slightly oblique. The malleoli tightly embrace the talus in all positions of the joint, so that any slight degree of side-to-side movement which may exist is simply due to stretching of the ligaments of the talofibular syndesmosis, and slight bending of the body of the fibula. The superior articular surface of the talus is broader in front than behind. In dorsiflexion, herefore, greater space is required between the two malleoli. This is obtained by a slight outward rotatory movement of the lower end of the fibula and a stretching of the ligaments of the syndesmosis; this lateral movement is facilitated by a slight gliding at the tibiofibular articulation, and possibly also by the bending of the body of the fibula. Of the ligaments, the deltoid is of very great power—so much so, that it usually resists a force which fractures the process of bone to which it is attached. Its middle portion, together with the calcaneofibular ligament, binds the bones of the leg firmly to the foot, and resists displacement in every direction. Its anterior and posterior fibers limit extension and flexion of the foot respectively, and the anterior fibers also limit abduction. The posterior talofibular ligament assists the calcaneofibular in resisting the displacement of the foot backward, and deepens the cavity for the reception of the talus. The anterior talofibular is a security against the displacement of the foot forward, and limits extension of the joint. 12

The movements of inversion and eversion of the foot, together with the minute changes in form by which it is applied to the ground or takes hold of an object in climbing, etc., are mainly effected in the tarsal joints; the joint which enjoys the greatest amount of motion being that between the talus and calcaneus behind and the navicular and cuboid in front. This is often called the **transverse tarsal joint,** and it can, with the subordinate joints of the tarsus, replace the ankle-joint in a great measure when the latter has become ankylosed. 13

Extension of the foot upon the tibia and fibula is produced by the Gastrocnemius, Soleus, Plantaris, Tibialis posterior, Peronæi longus and brevis, Flexor digitorum longus, and Flexor hallucis longus; *dorsiflexion,* by the Tibialis anterior, Peronæus tertius, Extensor digitorum longus, and Extensor hallucis proprius. 74 14

Note 74. The student must bear in mind that the Extensor digitorum longus and Extensor hallucis proprius are *extensors* of the toes, but *flexors* of the ankle; and that the Flexor digitorum longus and Flexor hallucis longus are *flexors* of the toes, but *extensors* of the ankle. [back]

7e. Intertarsal Articulations

(Articulationes Intertarseæ; Articulations of the Tarsus)

Talocalcaneal Articulation (*articulatio talocalcanea; articulation of the calcaneus and astragalus; calcaneo-astragaloid articulation*).—The articulations between the calcaneus and talus are two in number—anterior and posterior. Of these, the anterior forms part of the talocalcaneonavicular joint, and will be described with that articulation. The posterior or talocalcaneal articulation is formed between the posterior calcaneal facet on the inferior surface of the talus, and the posterior facet on the superior surface of the calcaneus. It is an arthrodial joint, and the two bones are connected by an articular capsule and by anterior, posterior, lateral, medial, and interosseous talocalcaneal ligaments. *1*

The Articular Capsule (*capsula articularis*).—The articular capsule envelops the joint, and consists for the most part of the short fibers, which are split up into distinct slips; between these there is only a weak fibrous investment. *2*

The Anterior Talocalcaneal Ligament (*ligamentum talocalcaneum anterius; anterior calcaneo-astragaloid ligament*) (Figs. 356, 359).—The anterior talocalcaneal ligament extends from the front and lateral surface of the neck of the talus to the superior surface of the calcaneus. It forms the posterior boundary of the talocalcaneonavicular joint, and is sometimes described as the **anterior interosseous ligament.** *3*

The Posterior Talocalcaneal Ligament (*ligamentum talocalcaneum posterius; posterior calcaneo-astragaloid ligament*) (Fig. 354).—The posterior talocalcaneal ligament connects the lateral tubercle of the talus with the upper and medial part of the calcaneus; it is a short band, and its fibers radiate from their narrow attachment to the talus. *4*

The Lateral Talocalcaneal Ligament (*ligamentum talocalcaneum laterale; external calcaneo-astragaloid ligament*) (Figs. 356, 359).—The lateral talocalcaneal ligament is a short, strong fasciculus, passing from the lateral surface of the talus, immediately beneath its fibular facet to the lateral surface of the calcaneus. It is placed in front of, but on a deeper plane than, the calcaneofibular ligament, with the fibers of which it is parallel. *5*

The Medial Talocalcaneal Ligament (*ligamentum talocalcaneum mediale; internal calcaneo-astragaloid ligament*).—The medial *6*

talocalcaneal ligament connects the medial tubercle of the back of the talus with the back of the sustentaculum tali. Its fibers blend with those of the plantar calcaneonavicular ligament (Fig. 354).

FIG. 357– Coronal section through right talocrural and talocalcaneal joints. (See enlarged image)

The Interosseous Talocalcaneal Ligament (*ligamentum talocalcaneum interosseum*) (Figs. 357, 359).—The interosseous talocalcaneal ligament forms the chief bond of union between the bones. It is, in fact, a portion of the united capsules of the talocalcaneonavicular and the talocalcaneal joints, and consists of two partially united layers of fibers, one belonging to the former and the other to the latter joint. It is attached,*above,* to the groove between the articular facets of the under surface of the talus; *below,* to a corresponding depression on the upper surface of the calcaneus. It is very thick and strong, being at least 2.5 cm. in breadth from side to side, and serves to bind the calcaneus and talus firmly together. 7

Synovial Membrane (Fig. 360).—The synovial membrane lines the capsule of the joint, and is distinct from the other synovial membranes of 8

the tarsus.

Movements.—The movements permitted between the talus and calcaneus are limited to gliding of the one bone on the other backward and forward and from side to side. 9

Talocalcaneonavicular Articulation (*articulatio talocalcaneonavicularis*).—This articulation is an arthrodial joint: the rounded head of the talus being received into the concavity formed by the posterior surface of the navicular, the anterior articular surface of the calcaneus, and the upper surface of the planter calcaneonavicular ligament. There are two ligaments in this joint: the articular capsule and the dorsal talonavicular. 10

The Articular Capsule (*capsula articularis*).—The articular capsule is imperfectly developed except posteriorly, where it is considerably thickened and forms, with a part of the capsule of the talocalcaneal joint, the strong interosseous ligament which fills in the canal formed by the opposing grooves on the calcaneus and talus, as above mentioned. 11

The Dorsal Talonavicular Ligament (*ligamentum talonaviculare dorsale; superior astragalonavicular ligament*) (Fig. 354).—This ligament is a broad, thin band, which connects the neck of the talus to the dorsal surface of the navicular bone; it is covered by the Extensor tendons. The plantar calcaneonavicular supplies the place of a plantar ligament for this joint. 12

Synovial Membrane.—The synovial membrane lines all parts of the capsule of the joint. 13

Movements.—This articulation permits of a considerable range of gliding movements, and some rotation; its feeble construction allows occasionally of dislocation of the other bones of the tarsus from the talus. 14

Calcaneocuboid Articulation (*articulatio calcaneocuboidea; articulation of the calcaneus with the cuboid*).—The ligaments connecting the calcaneus with the cuboid are five in number, viz., the articular capsule, the dorsal calcaneocuboid, part of the bifurcated, the long plantar, and the plantar calcaneocuboid. 15

The Articular Capsule (*capsula articularis*).—The articular capsule is an imperfectly developed investment, containing certain strengthened bands, which form the other ligaments of the joint. 16

The Dorsal Calcaneocuboid Ligament (*ligamentum calcaneocuboideum dorsale; superior calcaneocuboid ligament*) (Fig. 355).—The dorsal calcaneocuboid ligament is a thin but broad fasciculus, which passes between the contiguous surfaces of the calcaneus and cuboid, on the dorsal surface of the joint. 17

The Bifurcated Ligament (***ligamentum bifurcatum; internal calcaneocuboid; interosseous ligament***) (**Fig. 355**, **359**).—The bifurcated ligament is a strong band, attached behind to the deep hollow on the upper surface of the calcaneus and dividing in front in a Y-shaped manner into a calcaneocuboid and a calcaneonavicular part. The**calcaneocuboid part** is fixed to the medial side of the cuboid and forms one of the principal bonds between the first and second rows of the tarsal bones. The**calcaneonavicular part** is attached to the lateral side of the navicular. 18

The Long Plantar Ligament (***ligamentum plantare longum; long calcaneocuboid ligament; superficial long plantar ligament***) **(Fig. 358)**.—The long plantar ligament is the longest of all the ligaments of the tarsus: it is attached *behind* to the plantar surface of the calcaneus in front of the tuberosity, and in *front* to the tuberosity on the plantar surface of the cuboid bone, the more superficial fibers being continued forward to the bases of the second, third, and fourth metatarsal bones. This ligament converts the groove on the plantar surface of the cuboid into a canal for the tendon of the Peronæus longus. 19

The Plantar Calcaneocuboid Ligament (***ligamentum calcaneocuboideum plantare; short calcaneocuboid ligament; short plantar ligament***) **(Fig. 358)**.—The plantar calcaneocuboid ligament lies nearer to the bones than the preceding, from which it is separated by a little areolar tissue. It is a short but wide band of great strength, and extends from the tubercle and the depression in front of it, on the forepart of the plantar surface of the calcaneus, to the plantar surface of the cuboid behind the peroneal groove. 20

Synovial Membrane.—The synovial membrane lines the inner surface of the capsule and is distinct from that of the other tarsal articulations (Fig. 360). 21

Movements.—The movements permitted between the calcaneus and cuboid are limited to slight gliding movements of the bones upon each other. 22

The *transverse tarsal joint* is formed by the articulation of the calcaneus with the cuboid, and the articulation of the talus with the navicular. The movement which takes place in this joint is more extensive than that in the other tarsal joints, and consists of a sort of rotation by means of which the foot may be slightly flexed or extended, the sole being at the same time carried medially (inverted) or laterally (everted). 23

The Ligaments Connecting the Calcaneus and Navicular.—Though the calcaneus and navicular do not directly articulate, they are connected by two ligaments: the calcaneonavicular part of the bifurcated, and the plantar calcaneonavicular. 24

The **calcaneonavicular part of the bifurcated ligament** is described on page 354. 25

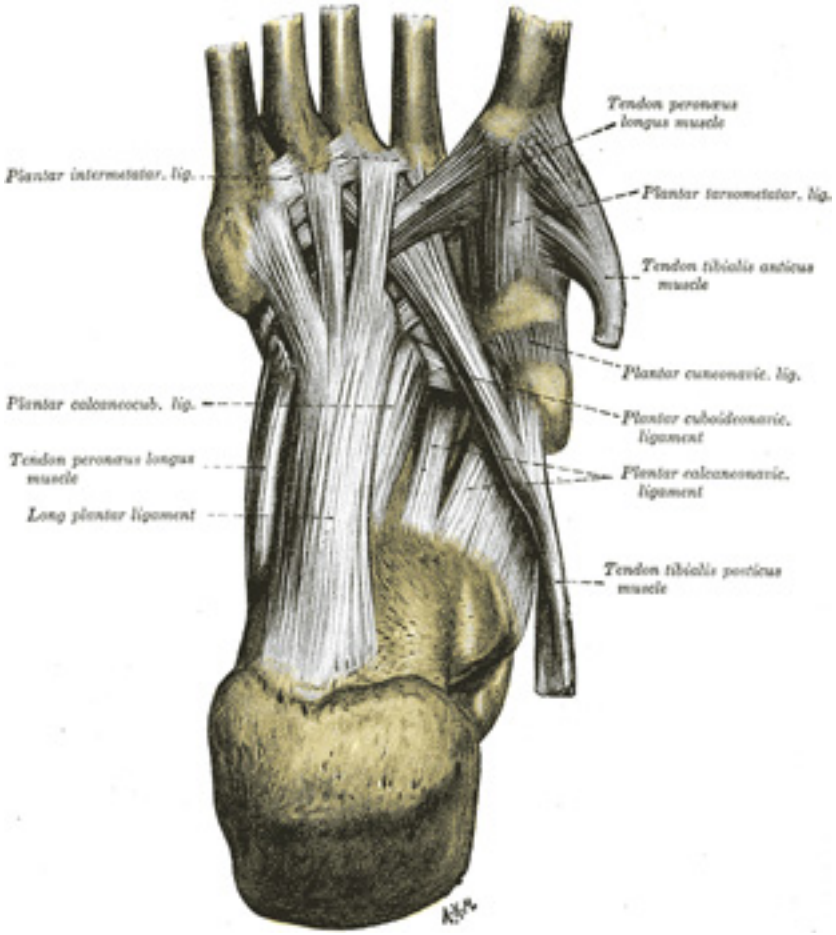

FIG. 358– Ligaments of the sole of the foot, with the tendons of the Peronæus longus, Tibialis posterior and Tibialis anterior muscles. (Quain.)
(See enlarged image)

The Plantar Calcaneonavicular Ligament (***ligamentum calcaneonaviculare plantare; inferior or internal calcaneonavicular ligament;***

***calcaneonavicular ligament*) (Figs. 354,358).**—The plantar calcaneonavicular ligament is a broad and thick band of fibers, which connects the anterior margin of the sustentaculum tali of the calcaneus to the plantar surface of the navicular. This ligament not only serves to connect the calcaneus and navicular, but supports the head of the talus, forming part of the articular cavity in which it is received. The **dorsal surface** of the ligament presents a fibrocartilaginous facet, lined by the synovial membrane, and upon this a portion of the head of the talus rests. Its **plantar surface** is supported by the tendon of the Tibialis posterior; its **medial border** is blended with the forepart of the deltoid ligament of the ankle-joint.

FIG. 359– Talocalcaneal and talocalcaneonavicular articulations exposed from above by removing the talus. (See enlarged image)

The plantar calcaneonavicular ligament, by supporting the head of the talus, is principally concerned in maintaining the arch of the foot. When it yields, the head of the talus is pressed downward, medialward, and forward by the weight of the body, and the foot becomes flattened, expanded, and turned lateralward, and exhibits the condition known as*flat-foot*. This ligament contains a considerable amount of elastic fibers, so as to give elasticity to the arch and spring to the foot; hence it is sometimes called the "spring" ligament. It is supported, on its plantar surface, by the tendon of the Tibialis posterior, which spreads out at its insertion into a number of fasciculi, to be attached to most of the tarsal and metatarsal bones. This prevents undue stretching of the ligament, and is a protection against the occurrence of flat-foot; hence muscular weakness is, in most cases, the primary cause of the deformity.

Cuneonavicular Articulation (*articulatio cuneonavicularis; articulation of the navicular with the cuneiform bones*).—The navicular is connected to the three cuneiform bones by dorsal and plantar ligaments. 28

The Dorsal Ligaments (*ligamenta navicularicuneiformia dorsalia*).—The dorsal ligaments are three small bundles, one attached to each of the cuneiform bones. The bundle connecting the navicular with the first cuneiform is continuous around the medial side of the articulation with the plantar ligament which unites these two bones (Figs. 354, 355). 29

The Plantar Ligaments (*ligamenta navicularicuneiformia plantaria*).—The plantar ligaments have a similar arrangement to the dorsal, and are strengthened by slips from the tendon of the Tibialis posterior (Fig. 358). 30

Synovial Membrane.—The synovial membrane of these joints is part of the great tarsal synovial membrane (Fig. 360). 31

Movements.—Mere gliding movements are permitted between the navicular and cuneiform bones. 32

Cuboideonavicular Articulation.—The navicular bone is connected with the cuboid by dorsal, plantar, and interosseous ligaments. 33

The Dorsal Ligament (*ligamentum cuboideonaviculare dorsale*).—The dorsal ligament extends obliquely forward and lateralward from the navicular to the cuboid bone (Fig. 355). 34

The Plantar Ligament (*ligamentum cuboideonaviculare plantare*).—The plantar ligament passes nearly transversely between these two bones (Fig. 358). 35

The Interosseous Ligament.—The interosseous ligament consists of strong transverse fibers, and connects the rough non-articular portions of the adjacent surfaces of the two bones Fig. 360). 36

Synovial Membrane.—The synovial membrane of this joint is part of the great tarsal synovial membrane (Fig. 360). 37

Movements.—The movements permitted between the navicular and cuboid bones are limited to a slight gliding upon each other. 38

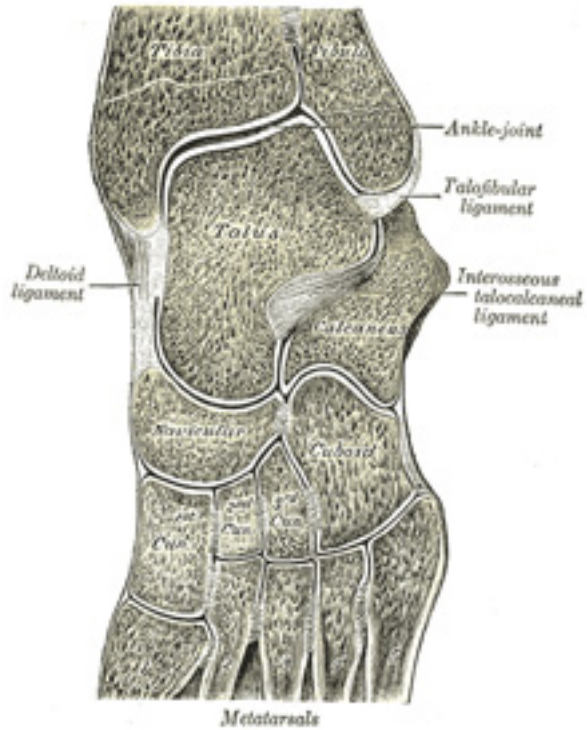

FIG. 360– Oblique section of left intertarsal and tarsometatarsal articulations, showing the synovial cavities. (See enlarged image)

Intercuneiform and Cuneocuboid Articulations.—The three cuneiform bones and the cuboid are connected together by dorsal, plantar, and interosseous ligaments. *39*

The Dorsal Ligaments (*ligamenta intercuneiformia dorsalia*).—The dorsal ligaments consist of three transverse bands: one connects the first with the second cuneiform, another the second with the third cuneiform, and another the third cuneiform with the cuboid. *40*

The Plantar Ligaments (*ligamenta intercuneiformia plantaria*).—The plantar ligaments have a similar arrangement to the dorsal, and are *41*

strengthened by slips from the tendon of the Tibialis posterior.

The Interosseous Ligaments (*ligamenta intercuneiformia interossea*).—The interosseous ligaments consist of strong transverse fibers which pass between the rough non-articular portions of the adjacent surfaces of the bones (Fig. 360). 42

Synovial Membrane.—The synovial membrane of these joints is part of the great tarsal synovial membrane (Fig. 360). 43

Movements.—The movements permitted between these bones are limited to a slight gliding upon each other. 44

1F. Tarsometatarsal Articulations

(Articulationes Tarsometatarseæ) 1

These are arthrodial joints. The bones entering into their formation are the first, second, and third cuneiforms, and the cuboid, which articulate with the bases of the metatarsal bones. The first metatarsal bone articulates with the first cuneiform; the second is deeply wedged in between the first and third cuneiforms articulating by its base with the second cuneiform; the third articulates with the third cuneiform; the fourth, with the cuboid and third cuneiform; and the fifth, with the cuboid. The bones are connected by dorsal, plantar, and interosseous ligaments.

The Dorsal Ligaments (*ligamenta tarsometatarsea dorsalia*).—The dorsal ligaments are strong, flat bands. The first metatarsal is joined to the first cuneiform by a broad, thin band; the second has three, one from each cuneiform bone; the third has one from the third cuneiform; the fourth has one from the third cuneiform and one from the cuboid; and the fifth, one from the cuboid (Figs. 354, 355). 2

The Plantar Ligaments (*ligamenta tarsometatarsea plantaria*).—The plantar ligaments consist of longitudinal and oblique bands, disposed with less regularity than the dorsal ligaments. Those for the first and second metatarsals are the strongest; the second and third metatarsals are joined by oblique bands to the first cuneiform; the fourth and fifth metatarsals are connected by a few fibers to the cuboid (Fig. 358). 3

The Interosseous Ligaments (*ligamenta cuneometatarsea interossia*).
—The interosseous ligaments are three in number. The first is the strongest, and passes from the lateral surface of the first cuneiform to the adjacent angle of the second metatarsal. The second connects the third cuneiform with the adjacent angle of the second metatarsal. The third connects the lateral angle of the third cuneiform with the adjacent side of the base of the third metatarsal. 4

Synovial Membrane (Fig. 360).—The synovial membrane between the first cuneiform and the first metatarsal forms a distinct sac. The synovial 5

membrane between the second and third cuneiforms behind, and the second and third metatarsal bones in front, is part of the great tarsal synovial membrane. Two prolongations are sent forward from it, one between the adjacent sides of the second and third, and another between those of the third and fourth metatarsal bones. The synovial membrane between the cuboid and the fourth and fifth metatarsal bones forms a distinct sac. From it a prolongation is sent forward between the fourth and fifth metatarsal bones.

Movements.—The movements permitted between the tarsal and metatarsal bones are limited to slight gliding of the bones upon each other. *6*

Nerve Supply.—The intertarsal and tarsometatarsal joints are supplied by the deep peroneal nerve.

7g. Intermetatarsal Articulations

(Articulationes Intermetatarseæ) *1*

The base of the first metatarsal is not connected with that of the second by any ligaments; in this respect the great toe resembles the thumb.

The bases of the other four metatarsals are connected by the dorsal, plantar, and interosseous ligaments. *2*

The Dorsal Ligaments (*ligamenta basium* [*oss. metatars.*] *dorsalia*) pass transversely between the dorsal surfaces of the bases of the adjacent metatarsal bones. *3*

The Plantar Ligaments (*ligamenta basium* [*oss. metatars*] *plantaria*).—The plantar ligaments have a similar arrangement to the dorsal. *4*

The Interosseous Ligaments (*ligamenta basium* [*oss. metatars.*] *interossea*).—The interosseous ligaments consist of strong transverse fibers which connect the rough non-articular portions of the adjacent surfaces. *5*

Synovial Membranes (Fig. 360).—The synovial membranes between the second and third, and the third and fourth metatarsal bones are part of the great tarsal synovial membrane; that between the fourth and fifth is a prolongation of the synovial membrane of the cuboideometatarsal joint. *6*

Movements.—The movement permitted between the tarsal ends of the metatarsal bones is limited to a slight gliding of the articular surfaces upon one another. *7*

The heads of all the metatarsal bones are connected together by the transverse metatarsal ligament. *8*

The Transverse Metatarsal Ligament.—The transverse metatarsal ligament is a narrow band which runs across and connects together the heads *9*

of all the metatarsal bones; it is blended anteriorly with the plantar (glenoid) ligaments of the metatarsophalangeal articulations. Its plantar surface is concave where the Flexor tendons run below it; above it the tendons of the Interossei pass to their insertions. It differs from the transverse metacarpal ligament in that it connects the metatarsal to the others.

The Synovial Membranes in the Tarsal and Tarsometatarsal Joints (Fig. 360).—The synovial membranes found in the articulations of the tarsus and metatarsus are six in number: one for the talocalcaneal articulation; a second for the talocalcaneonavicular articulation; a third for the calcaneocuboid articulation; and a fourth for the cuneonavicular, intercuneiform, and cuneo-cuboid articulations, the articulations of the second and third cuneiforms with the bases of the second and third metatarsal bones, and the adjacent surfaces of the bases of the second, third, and fourth metatarsal bones; a fifth for the first cuneiform with the metatarsal bone of the great toe; and a sixth for the articulation of the cuboid with the fourth and fifth metatarsal bones. A small synovial cavity is sometimes found between the contiguous surfaces of the navicular and cuboid bones.

7h. Metatarsophalangeal Articulations

(Articulationes Metatarsophalangeæ) *1*

The metatarsophalangeal articulations are of the condyloid kind, formed by the reception of the rounded heads of the metatarsal bones in shallow cavities on the ends of the first phalanges.

The ligaments are the plantar and two collateral. *2*

The Plantar Ligaments (*ligamenta accessoria plantaria; glenoid ligaments of Cruveilhier*).—The plantar ligaments are thick, dense, fibrous structures. They are placed on the plantar surfaces of the joints in the intervals between the collateral ligaments, to which they are connected; they are loosely united to the metatarsal bones, but very firmly to the bases of the first phalanges. Their plantar surfaces are intimately blended with the transverse metatarsal ligament, and grooved for the passage of the Flexor tendons, the sheaths surrounding which are connected to the sides of the grooves. Their deep surfaces form part of the articular facets for the heads of the metatarsal bones, and are lined by synovial membrane. *3*

The Collateral Ligaments (*ligamenta collateralia; lateral ligaments*).—The collateral ligaments are strong, rounded cords, placed one on either side of each joint, and attached, by one end, to the posterior tubercle on the side of the head of the metatarsal bone, and, by the other, to the contiguous extremity of the phalanx. *4*

The place of **dorsal ligaments** is supplied by the Extensor tendons on the dorsal surfaces of the joints. *5*

Movements.—The movements permitted in the metatarsophalangeal articulations are flexion, extension, abduction, and adduction.

7i. Articulations of the Digits

(Articulationes Digitorum Pedis; Articulations of the Phalanges) 1

The interphalangeal articulations are ginglymoid joints, and each has a plantar and two collateral ligaments.

The arrangement of these ligaments is similar to that in the metatarsophalangeal articulations: the Extensor tendons supply the places of dorsal ligaments. 2

Movements.—The only movements permitted in the joints of the digits are flexion and extension; these movements are more extensive between the first and second phalanges than between the second and third. The amount of flexion is very considerable, but extension is limited by the plantar and collateral ligaments.

7j. Arches of the Foot

In order to allow it to support the weight of the body in the erect posture with the least expenditure of material, the foot is constructed of a series of arches formed by the tarsal and metatarsal bones, and strengthened by the ligaments and tendons of the foot. 1

The main arches are the **antero-posterior arches,** which may, for descriptive purposes, be regarded as divisible into two types—a medial and a lateral. The **medial arch** (see Fig. 290, page 276) is made up by the calcaneus, the talus, the navicular, the three cuneiforms, and the first, second, and third metatarsals. Its summit is at the superior articular surface of the talus, and its two extremities or piers, on which it rests in standing, are the tuberosity on the plantar surface of the calcaneus posteriorly and the heads of the first, second, and third metatarsal bones anteriorly. The chief characteristic of this arch is its elasticity, due to its height and to the number of small joints between its component parts. Its weakest part, *i. e.*,the part most liable to yield from overpressure, is the joint between the talus and navicular, but this portion is braced by the plantar calcaneonavicular ligament, which is elastic and is thus able to quickly restore the arch to its pristine condition when the disturbing force is removed. The ligament is strengthened medially by blending with the deltoid ligament of the ankle-joint, and is supported inferiorly by the tendon of the Tibialis posterior, which is spread out in a fanshaped insertion and prevents undue tension of the ligament or such an amount of stretching as would permanently elongate it. The arch is further supported by the plantar aponeurosis, by the small muscles in the sole of the foot, by the tendons of the Tibialis anterior and posterior and Peronæus longus, and by the ligaments of all the articulations involved. The **lateral arch** (see Fig. 291, page 277) is composed of the calcaneus, the cuboid, and the fourth and fifth metatarsals. Its summit is at the talocalcaneal articulation, and its chief joint is the calcaneocuboid, which possesses a special mechanism for locking, and allows only a limited movement. The most marked features of this arch are its solidity and its slight elevation; two strong ligaments, the long plantar and the plantar calcaneocuboid, together with the Extensor tendons and the short muscles of the little toe, preserve its integrity. 2

While these medial and lateral arches may be readily demonstrated as the component antero-posterior arches of the foot, yet the **fundamental longitudinal arch** is contributed to by both, and consists of the calcaneus, cuboid, third cuneiform, and third metatarsal: all the other bones of the 3

foot may be removed without destroying this arch.

In addition to the longitudinal arches the foot presents a series of **transverse arches.** At the posterior part of the metatarsus and the anterior part of the tarsus the arches are complete, but in the middle of the tarsus they present more the characters of half-domes the concavities of which are directed downward and medialward, so that when the medial borders of the feet are placed in apposition a complete tarsal dome is formed. The transverse arches are strengthened by the interosseous, plantar, and dorsal ligaments, by the short muscles of the first and fifth toes (especially the transverse head of the Adductor hallucis), and by the Peronæus longus, whose tendon stretches across between the piers of the arches. *4*

Bibliography

R. FICK: Handbuch der Anatomie und Mechanik der Gelenke (Bardeleben's Handbuch der Anatomie).